

*Int. J. Oral Maxillofac. Surg.* 2024; xx: 1–8  
<https://doi.org/10.1016/j.ijom.2024.02.006>, available online at <https://www.sciencedirect.com>

International Journal of  
*Oral &  
Maxillofacial  
Surgery*

## Clinical Paper Orthognathic Surgery

# The surgery-first approach for orthognathic correction of maxillary deficiency—is it stable? Three-dimensional assessment of CBCT scans and digital dental models

H. Saghafi<sup>a</sup>, P. Benington<sup>a</sup>, X. Ju<sup>b</sup>,  
A. Ayoub<sup>a</sup>

<sup>a</sup>Glasgow University Dental Hospital and School, Glasgow, UK; <sup>b</sup>Medical Device Unit, Department of Clinical Physics and Bioengineering, NHS Greater Glasgow and Clyde, West Glasgow Ambulatory Hospital, Glasgow, UK

H. Saghafi, P. Benington, X. Ju, A. Ayoub: The surgery-first approach for orthognathic correction of maxillary deficiency—is it stable? Three-dimensional assessment of CBCT scans and digital dental models. *Int. J. Oral Maxillofac. Surg.* 2024; xx: 1–8. © 2024 The Author(s). Published by Elsevier Inc. on behalf of International Association of Oral and Maxillofacial Surgeons. This is an open access article under the CC BY license (<http://creativecommons.org/licenses/by/4.0/>).

**Abstract.** The aim of this study was to determine the skeletal stability of Le Fort I maxillary advancement following the surgery-first approach, by three-dimensional (3D) assessment of cone beam computed tomography (CBCT) scans and digital dental models. CBCT scans of 25 class III patients obtained 1 week preoperatively (T0) and 1 week (T1) and 6 months (T2) postoperatively were superimposed to measure surgical movements (T0–T1) and skeletal relapse (T1–T2). The distorted dentition of the CBCT scans at T1 was replaced with 3D images of the dental models to assess the postoperative occlusion. Surgical movements of the maxilla (mean  $\pm$  standard deviation values) were  $6.79 \pm 2.30$  mm advancement,  $1.28 \pm 1.09$  mm vertically, and  $0.71 \pm 0.79$  mm mediolaterally. Horizontal rotation (yaw) was  $1.56^\circ \pm 1.21^\circ$ , vertical rotation (pitch)  $1.86^\circ \pm 1.88^\circ$ , and tilting (roll)  $1.63^\circ \pm 1.54^\circ$ . At T2, the posterior relapse was  $0.72 \pm 0.43$  mm ( $P = 0.001$ ) and relapse in pitch was  $1.56^\circ \pm 1.42^\circ$  ( $P = 0.007$ ). There was no correlation between the size of the surgical movements and the amount of relapse. A weak correlation was noted between the number of teeth in occlusal contact immediately following surgery and relapse of maxillary roll ( $r = -0.434$ ,  $P = 0.030$ ). The stability of maxillary advancement with the surgery-first approach was satisfactory and was not correlated with the quality of the immediate postoperative occlusion.

**Keywords:** Orthognathic surgical procedures; Stability; Dental occlusion; Surgery-first approach; Three-dimensional imaging.

Accepted for publication 21 February 2024  
Available online xxxx

Skeletal stability is one of the important criteria for determining the success of orthognathic surgery and can potentially be affected by dental, skeletal, and surgical factors<sup>1</sup>. Dental factors include incisor inclinations, overjet, overbite, depth of the curve of Spee, mandibular and maxillary plane angles, and quality of the occlusion. Skeletal factors include the severity of the maxillomandibular deformities, while surgical factors include the rotation of the maxillomandibular complex, magnitude of the surgical movements, and method of fixation<sup>2-4</sup>.

The conventional orthognathic approach is 12–24 months of preoperative orthodontic treatment, followed by surgical correction of the skeletal deformity and a phase of postoperative orthodontics. In 2009, Nagasaka et al.<sup>5</sup> proposed the surgery-first approach (SFA), which eliminates the preoperative orthodontic treatment. The surgery is performed first and the orthodontic treatment is performed entirely postoperatively. Subsequent studies have described several advantages of the SFA, including early improvement in facial profile, greater patient satisfaction, and a shorter duration of treatment<sup>3,6,7</sup>.

However, it has been reported that the SFA may increase the risk of skeletal relapse due to the relatively sub-optimal immediate postsurgical occlusion<sup>8,9</sup>. In the conventional approach, the preoperative orthodontic treatment is aimed at maximizing the quality of the immediate postoperative occlusion, whereas in the SFA, orthodontic alignment and decompensation are performed after surgical correction. The impact of the quality of the postoperative occlusion on skeletal stability in patients undergoing the SFA has not yet been fully investigated<sup>5,10-13</sup>.

Some studies have reported no statistically significant difference in postoperative stability between the SFA and conventional approach<sup>14-16</sup>, while others have concluded that the SFA is associated with less stable results<sup>17,18</sup>. In most previous studies, skeletal stability was evaluated using two-dimensional (2D) cephalometric radiographs, which do not allow mediolateral skeletal changes to be evaluated<sup>14,18-22</sup>. In addition, the individual landmarks that were used in the analyses, including pogonion, point A, and point B, are subject to remodelling following surgery, and therefore are of doubtful validity for the evaluation of the skeletal

stability. Other studies have used the same landmarks on three-dimensional (3D) cone beam computed tomography (CBCT) scans to evaluate skeletal relapse, but the details of superimposition of the corresponding 3D images were missing<sup>23-25</sup>.

Therefore, the aims of this study were firstly to assess in 3D the skeletal stability of Le Fort I maxillary advancement for the correction of maxillary deficiency following the SFA, and secondly to explore the correlation of the skeletal stability and the quality of the immediate postoperative occlusion. In order to achieve the aims, this study employed a novel hybrid model in which the dentition of the immediate postoperative CBCT scan is replaced with the scanned dental model.

## Materials and methods

This retrospective cohort study included 25 skeletal class III patients who were assessed in a multidisciplinary orthognathic clinic. The patients were diagnosed with maxillary deficiency and underwent Le Fort I maxillary advancement followed by fixed appliance orthodontic treatment in accordance with the SFA. The surgical procedures were conducted by the same surgeon and followed the same surgical protocol. No presurgical orthodontic treatment was performed. The standard protocol followed in each case included clinical diagnosis, 3D digital prediction planning of the occlusion and soft tissue changes, and printing of the occlusal guiding wafer. The surgical occlusion agreed between the surgeon and the orthodontist was based on the required postsurgical orthodontic treatment and the dental decompensation. The orthodontic treatment was started immediately following the surgery. Patients with cleft lip and palate and those with a history of dentofacial trauma or previous facial surgery were excluded from the study. All of the patients had CBCT scans performed within 1 week prior to surgery (T0) and at 1 week (T1) and 6 months (T2) following surgery.

The CBCT scans in DICOM file format (Digital Imaging and Communications in Medicine) were converted to 3D STL format (Standard Tessellation Language) using Maxilim software (Medicim NV, Mechelen, Belgium). Two reference planes were defined on the scan images: a horizontal

plane (axial) passing through left and right orbitale and left porion, and a vertical plane (sagittal) perpendicular to the horizontal plane passing through nasion. A second vertical plane (coronal) was automatically generated perpendicular to the other two, passing through sella. The T0, T1, and T2 3D models were then imported into VRMesh software (Virtual Grid, Bellevue, WA, USA) and transformed such that the coordinates of the nasion point were set as the origin (0, 0, 0).

The 1-week (T1) and 6-month (T2) postoperative 3D models were registered to the preoperative (T0) 3D model using surface-based registration (Fig. 1). The anterior cranial base, zygomatic arches, and forehead were considered stable regions, unaffected by surgery, and were used for the registration of the corresponding scans. Three landmarks sited at the maxillary right and left greater palatine foramina and the incisive foramen were selected. The 3D surgical movement (T0–T1) and skeletal changes (T1–T2) were assessed by measuring the translations and rotations of the coordinates of these three landmarks. Movements were calculated in six degrees of freedom: along the X, Y, and Z axes, i.e. left/right, anterior/posterior, and superior/inferior directions, and pitch, roll, and yaw.

The postoperative CBCT scans (T1) were not suitable for the analysis of the immediate postoperative occlusion due to the distortion of the dentition and streak artefacts. Hence, the dental study models that were taken 1 day before surgery were scanned using an intraoral scanner (TRIOS 3; 3shape A/S, Copenhagen, Denmark) and the scanned images imported into IPS CaseDesigner software (KLS Martin, Tuttlingen, Germany) for replacement of the dentition in the T1 CBCT scans. Following conversion of the CBCT DICOM files to 3D STL models, the right and left condylar heads, mesio-buccal cusp of the upper right and left first molars, and point of contact between the two upper central incisors were selected. The IPS CaseDesigner software automatically registered the scanned dental models with the dentition of the CBCT scans based on the iterative closest point (ICP) algorithm. This allowed the generation of a virtual 3D skull model that incorporated the scanned dental occlusion (Fig. 2).

The 3D models were then imported into VRMesh software (Virtual Grid)

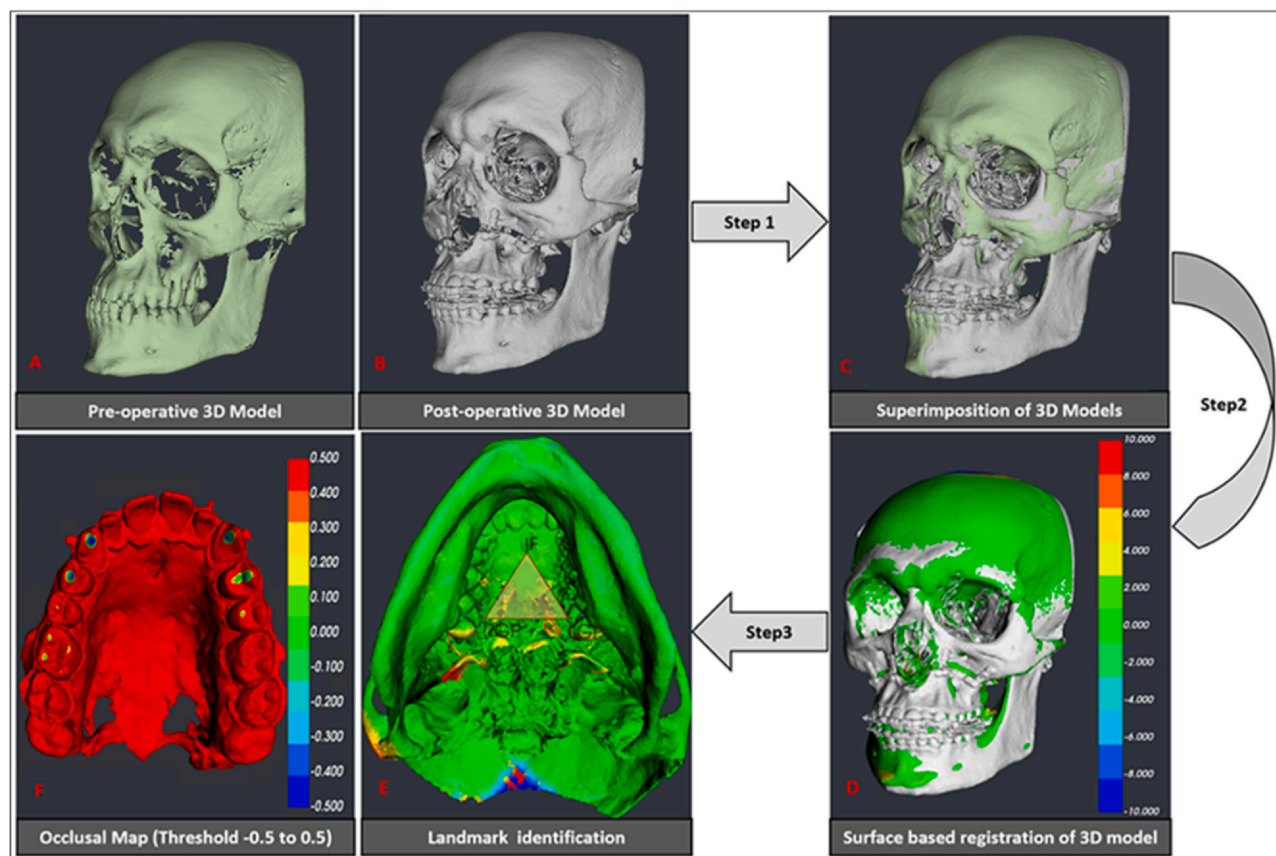


Fig. 1. Visual representation of the steps for surface-based registration to evaluate postoperative outcomes. Step 1: the preoperative (A) and postoperative (B) 3D models were superimposed on the anterior cranial base, zygomatic arches, and forehead (C). Step 2: surface-based registration of the preoperative to the postoperative model (D). Step 3: landmark identification and formation of the maxillary triangular plane (E) for calculation of the translations along the X-, Y-, and Z-axes and pitch, roll, and yaw. Step 4: generation of the occlusal map (threshold  $-0.5$  to  $0.5$ ) to assess the quality of the occlusion (F).

for visualization of the occlusal contacts and the generation of an occlusal colour-coded map on the maxillary dentition. Colour-coding indicated the proximity of the occlusal surfaces with a range between  $-0.5$  mm and  $+0.5$  mm, which was based on a pilot study. To assess the quality of the occlusion, the dental arch was subdivided into the anterior region (from right canine to left canine) and posterior regions (from premolars to second molars on the right and the left sides). The colour-coded map was then used to identify whether occlusal contacts existed in each of these three regions. The overjet, overbite, and number of teeth in occlusal contact were also recorded.

#### Data analysis

The sample size for this study was calculated using G\*Power software version 3.1.9.7 (March 17, 2020) (Heinrich-Heine-Universität Düsseldorf, Düsseldorf, Germany). At a significance level of  $P < 0.05$ , and

with a 95% confidence interval and power of 0.90, 19 subjects were required to detect a 1-mm skeletal change.

Normally distributed data were analysed using the paired *t*-test, while non-normally distributed data were analysed using the Wilcoxon signed-rank test.

To assess intra-examiner reliability, all of the CBCT measurements were repeated after 4 weeks. To assess the intra-examiner reliability of the occlusion analysis using IPS CaseDesigner, the same researcher repeated the replacement of the dentition in the CBCT scans after a 4-week interval for 50% of the cases and measured the occlusal contacts again. The error of landmarking and the reproducibility of the measurement method were calculated in terms of the absolute mean difference between the two measurements. The intra-class correlation coefficients (ICC) for the correlation between the two measurements were computed using a two-way mixed model to test

for the absolute agreement, with a 95% confidence interval. The size of the measurement error was calculated using Dahlberg's formula.

The relapse ratio percentage was calculated as  $((T1-T2) \times 100)/(T0-T1)$ . The range of relapse was categorized into four groups: group 1,  $< 0.5$  mm; group 2,  $0.5-1$  mm; group 3,  $1-1.5$  mm; group 4,  $> 1.5$  mm. Pearson or Spearman correlation analysis was applied to evaluate the relationship between skeletal relapse ( $T1-T2$ ) and both the magnitude of the surgical movement ( $T0-T1$ ) and the quality of the occlusion achieved immediately after surgery. Probabilities of less than 0.05 were accepted as significant.

#### Results

The mean age of the 25 patients included in this study was  $29.12 \pm 10.86$  years. Fourteen patients were male and 11 were female. A genioplasty was performed in four cases. The mean duration of the postoperative orthodontic treatment was



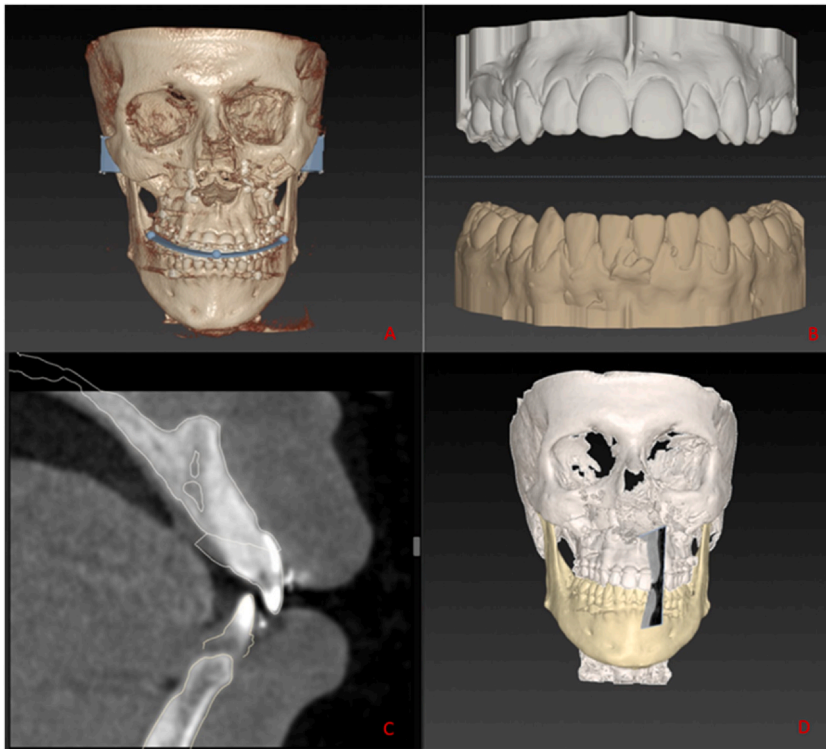


Fig. 2. Replacement of the dentition in IPS CaseDesigner. (A) CBCT STL model in IPS CaseDesigner software; the left and right condyle, mesiobuccal cusps of the maxillary first molars, and central incisors contact point are marked. (B) Scanned dental models. (C) Sagittal view of the 3D CBCT skull model showing the fused scanned models. (D) Frontal view showing the CBCT occlusion replaced by the scanned dental models.

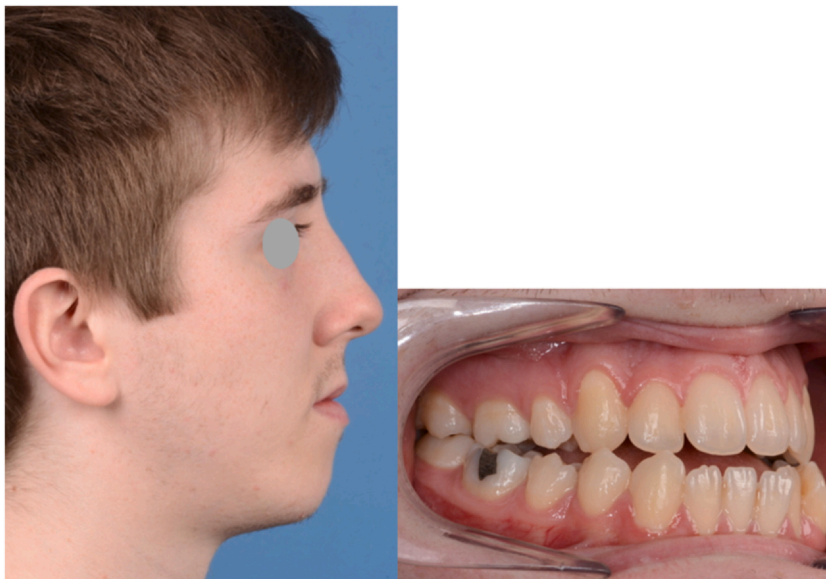

Fig. 3. Preoperative facial and occlusal views of one of the patient cases.

11.7 ± 5.7 months, and all patients completed the postoperative orthodontic treatment. Figs. 3–5 show the profile and occlusion before surgery, immediately after surgery, and on completion of orthodontic treatment for one of the patient cases included in this study.

Excellent correlations were detected between the repeated digitizations of the landmarks in the X, Y, and Z axes at T0, T1, and T2. Only the x coordinate of the incisive foramen landmark showed any statistically significant difference: 0.12 ± 0.29 mm at T0 ( $P=0.048$ ) and

–0.09 ± 0.26 mm at T2 ( $P=0.011$ ). The measurement error was found to be less than 0.5 mm using Dahlberg's formula. There was also an excellent correlation between repeated measurements of the occlusion ( $r=0.991$ ). The intra-examiner mean difference in occlusal contacts in IPS CaseDesigner software was 0.07 ± 0.27 mm ( $P=0.337$ ).

The preoperative overjet (mean ± standard deviation) was  $-2.75 \pm 2.04$  mm and overbite was  $-2.04 \pm 2.53$  mm. Both showed a significant improvement at 1 week following surgery (change in overjet  $6.94 \pm 2.42$  mm,  $P < 0.001$ ; change in overbite  $2.56 \pm 2.58$  mm,  $P < 0.001$ ). At 1 week following surgery, 13 patients had occlusal contacts in two regions, with the average number of the teeth in contact being  $3.85 \pm 1.89$  (Table 1).

The surgical movement (T0 to T1) of the maxilla (mean ± standard deviation) was  $6.79 \pm 2.30$  mm forward,  $1.28 \pm 1.09$  mm vertically, and  $0.71 \pm 0.79$  mm mediolaterally. The horizontal maxillary rotation (yaw) was  $1.56^\circ \pm 1.21^\circ$ , the vertical rotation (pitch) was  $1.86^\circ \pm 1.88^\circ$ , and tilting (roll) was  $1.63^\circ \pm 1.54^\circ$ .

The mean maxillary relapse in the posterior direction was  $0.72 \pm 0.43$  mm ( $P=0.001$ ). The vertical relapse was  $0.57 \pm 0.47$  mm, with 60% in the downward direction and 40% in the upward direction. The mediolateral relapse was  $0.30 \pm 0.33$  mm, with 48% to the right and 52% to the left. Relapse in roll ( $1.28^\circ \pm 0.82^\circ$ ) and yaw ( $0.81^\circ \pm 0.68^\circ$ ) was detected. The relapse in pitch of  $1.56^\circ \pm 1.42^\circ$  was statistically significant ( $P=0.007$ ). In 19 cases, the relapse did not exceed 1.0 mm. In 14 cases the relapse was less than 10% of the total surgical movement, in eight cases it was between 10% and 20%, and in three cases it was more than 20%.

Regarding the correlation between relapse and the surgical movements and between relapse and the postoperative occlusion, a weak correlation was noted between the roll, yaw, and pitch of the surgical movements and the detected relapse at T2. Interestingly, there was no statistically significant correlation between the magnitude of the surgical movements and the detected relapse at 6 months. A weak correlation was detected between maxillary relapse of roll and the number of the teeth in occlusal contact ( $r=-0.434$ ,  $P=0.030$ ). No correlation was found between the

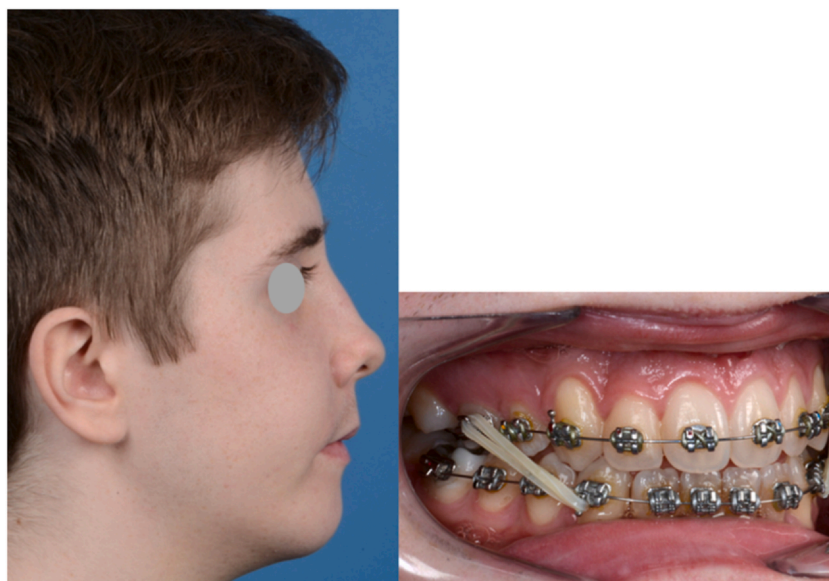


Fig. 4. Immediate postoperative facial and occlusal views of the same patient case.

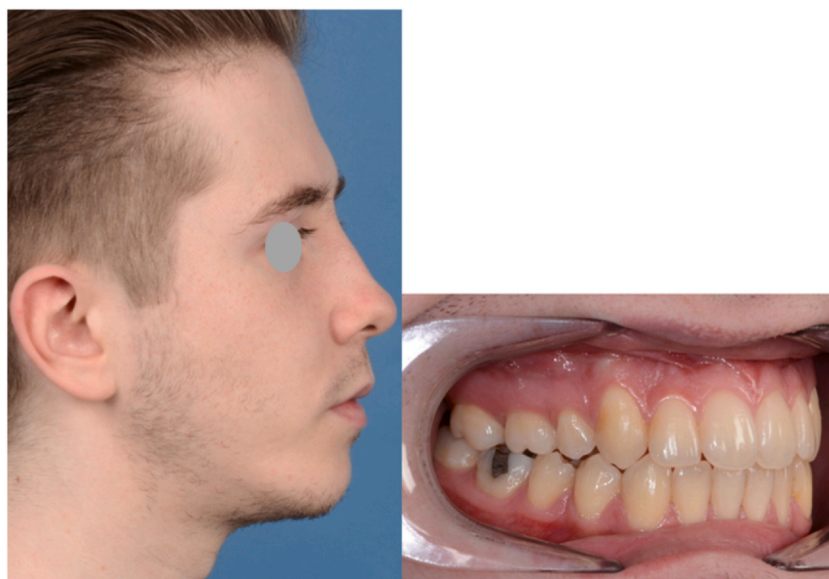

Fig. 5. Facial and occlusal views at the completion of treatment.

quality of the occlusion and the stability of the anteroposterior maxillary movement (Table 2).

### Discussion

This study is novel in investigating the 3D relationship between the immediate postoperative occlusion and skeletal stability following Le Fort I maxillary advancement by SFA, using CBCT scans and the scanned dental models.

The study findings demonstrated a statistically significant relapse in maxillary pitch of  $1.56^\circ \pm 1.43^\circ$  ( $P = 0.007$ ) and posterior shift of  $0.72 \pm 0.43$  mm ( $P = 0.001$ ). However, this is considered to be of limited clinical significance, and the maxilla remained stable within 1.0 mm and  $1.5^\circ$  of its immediate post-surgical position. In 19 cases, the horizontal maxillary relapse was less than 1.0 mm. This is contrary to the findings of Liao et al.<sup>26</sup>, who showed negligible relapse of the maxilla ( $<0.5$  mm and  $<0.5^\circ$ ). On the other hand, Lo et al.<sup>9</sup> reported significant posterior relapse at point A ( $1.0 \pm 0.9$  mm,  $P < 0.001$ ) and at anterior nasal spine (ANS) ( $1.5 \pm 1.2$  mm,  $P < 0.001$ ). In these two previous studies, the analysis was based on individual landmarks including point A, which is subject to remodelling, and ANS, which is usually removed or trimmed during surgery. In addition, their method of CBCT registration was not reported. Baek et al.<sup>27</sup> reported no significant relapse in the anteroposterior position of point A. However, in their study, the maxillary movement was limited to 4.3 mm of posterior impaction without notable surgical change in the anteroposterior direction. Similarly, Kim et al.<sup>18</sup> reported no relapse of the maxilla in cases with a small anterior–posterior surgical

Table 1. Occlusal characteristics of the 25 class III patients treated with the surgery-first approach.

Occlusion	Preoperative (T0)	1-week postoperative (T1)	Change (T0–T1)	P-value
	Mean $\pm$ standard deviation			
Overjet (mm)	$-2.75 \pm 2.04$	$4.19 \pm 2.31$	$6.94 \pm 2.42$	$< 0.001^*$
Overbite (mm)	$-2.04 \pm 2.53$	$0.52 \pm 1.39$	$2.56 \pm 2.58$	$< 0.001^*$
Number of teeth in contact	$3.44 \pm 3.28$	$3.85 \pm 1.89$	$0.38 \pm 3.69$	0.463
Number of occlusal regions	$1.56 \pm 1.1$	$2.12 \pm 0.71$	$0.53 \pm 1.27$	0.041
	n (%)			
Contact distribution				
Anterior region	12 (48%)	16 (64%)		
Right posterior region	14 (56%)	19 (76%)		
Left posterior region	12 (48%)	17 (68%)		
Number of regions with occlusal contacts				
Three regions	7 (28%)	7 (28%)		
Two regions	5 (20%)	13 (52%)		
One region	8 (32%)	5 (20%)		

\*Significant,  $P < 0.05$ .

Table 2. Correlation between relapse at 6 months and the surgical movement, as well as the immediate postoperative occlusion.

Relapse (T1–T2)	Distribution of occlusal contacts	Number of teeth in contact	Overjet	Overbite	Surgical movement (T0–T1)
Translation (mm)					
Left/right	$r = 0.138$ $P = 0.512$	$r = 0.065$ $P = 0.757$	$r = -0.159$ $P = 0.449$	$r = 0.179$ $P = 0.392$	$r = 0.209$ $P = 0.316$
Posterior/anterior	$r = -0.104$ $P = 0.621$	$r = -0.255$ $P = 0.219$	$r = 0.249$ $P = 0.231$	$r = -0.165$ $P = 0.430$	$r = 0.204$ $P = 0.329$
Superior/inferior	$r = 0.273$ $P = 0.187$	$r = 0.182$ $P = 0.385$	$r = 0.072$ $P = 0.733$	$r = 0.324$ $P = 0.114$	$r = 0.058$ $P = 0.784$
Rotation (°)					
Pitch	$r = -0.083$ $P = 0.694$	$r = -0.075$ $P = 0.721$	$r = 0.289$ $P = 0.161$	$r = -0.080$ $P = 0.705$	$r = 0.271$ $P = 0.190$
Roll	$r = 0.255$ $P = 0.219$	$r = -0.434$ $P = 0.030^*$	$r = 0.151$ $P = 0.472$	$r = -0.073$ $P = 0.730$	$r = 0.143$ $P = 0.495$
Yaw	$r = 0.310$ $P = 0.132$	$r = -0.367$ $P = 0.071$	$r = 0.299$ $P = 0.147$	$r = 0.291$ $P = 0.158$	$r = 0.147$ $P = 0.482$

T0, 1 week preoperative; T1, 1 week postoperative; T2, 6 months postoperative. \*Significant,  $P < 0.05$ .

movement ( $0.8 \pm 1.3$  mm) and without any notable vertical movement. All of these previous studies assessed the stability of the SFA in patients who had bimaxillary surgery<sup>9,18,26,27</sup>. They all agreed that the greater the clockwise rotation of the mandible, the greater the relapse of the maxilla following surgery<sup>28</sup>. Therefore, the present study was limited to patients who had undergone Le Fort I osteotomy only in order to avoid the impact of mandibular stability on the maxillary relapse.

The classic hierarchy of stability published by Proffit et al.<sup>29</sup> classified the relapse following orthognathic surgery according to 2D cephalometric analysis. Changes of less than 2 mm were not included, as these were within the error of the method and clinically insignificant. Although 2 mm of relapse might be a relatively small proportion of a 10-mm maxillary advancement, it is 50% of a 4-mm surgical movement. The presented subdivision of the percentage of relapse in the current study addressed this issue and provided a meaningful measure to evaluate the stability of orthognathic surgery in relation to the surgical movements achieved.

Landmarks that are altered during surgery were excluded in this study, including ANS and those that undergo postoperative remodelling such as point A, which can misinform the assessment of surgical stability. Stable landmarks were selected to identify the maxillary plane and measure maxillary movements in six degrees of freedom. In contrast to previous studies<sup>30</sup>, no statistically significant correlation between the magnitude of the surgical movements and relapse was detected. A possible explanation for the relapse noted in the pitch of the maxilla might be due to the settling of the maxilla

following the removal of occlusal interferences during the postsurgical orthodontic treatment.

The relationship between the occlusion and relapse in SFA cases has not been studied before. Previous studies have reported the correlation between the preoperative<sup>9</sup> or planned occlusion and relapse<sup>24,26</sup>. To prevent relapse, stabilization of the postoperative occlusion with the surgical wafer has been reported<sup>3,18,23,27,31</sup>. However, the analysis of occlusion in these studies was limited to incisor inclinations, occlusal cant, and preoperative overjet and overbite. It was therefore important for the current study to evaluate the immediate postoperative occlusion more comprehensively in cases managed with the SFA, to assess its impact on the stability of the osteotomy segments.

This study is novel in replacing the dentition of the postoperative CBCT scans with digital dental models to allow accurate quantitative assessment of the occlusion. Baan et al.<sup>32</sup> assessed the accuracy of IPS CaseDesigner and OrthoAnalyzer software in replacing the dentition of CBCT scans with scanned dental models. Comparisons were made to the laser scanned skull with dentition, which was used as the gold standard. IPS CaseDesigner showed a high level of accuracy, with a mean difference of 0.2 mm, which was less than the voxel size of the CBCT (0.40 mm)<sup>32</sup>.

In this study, it was considered that the distance between +0.5 mm and -0.5 mm represented occlusal contact and that an inter-occlusal distance of 0 mm represents an edge-to-edge occlusion. This provided the necessary guide to generate the colour-coded occlusal map, which showed the distribution and number of occlusal contacts within the defined regions. Detailed

analysis of the occlusal maps demonstrated that the relapse of the Le Fort I maxillary advancement was weakly correlated ( $r = -0.434$ ) with the number of teeth in contact in the immediate postoperative occlusion. This finding suggests a limited impact of the quality of the postoperative occlusion on the skeletal stability of Le Fort I osteotomy in SFA patients.

In summary, this study demonstrated a satisfactory level of stability of Le Fort I maxillary advancement in a cohort of SFA patients. This adds to the overall merits of this approach, which include a significantly reduced treatment duration and a reduced number of clinical appointments, whilst achieving comparable occlusal outcomes<sup>33</sup>. The SFA provides an immediate correction of the skeletal discrepancy, which has been shown to improve patient quality of life<sup>34</sup> without compromising the quality of the facial aesthetics<sup>35</sup>.

The main limitation of this study was the single cohort of patients who had followed a single treatment approach. The relatively short-term follow-up period is also acknowledged. Multicentre studies with a longer follow-up assessment are therefore recommended. Despite the fact that prospective randomized studies provide the highest level of evidence, the authors believe it would be unethical to randomly allocate patients to the conventional orthodontics-first approach when it would be possible to achieve comparable results with a shorter duration of treatment using the SFA.

In conclusion, the skeletal stability of the surgery-first approach for the correction of maxillary deficiency is satisfactory and was found not to be correlated to the magnitude of anteroposterior surgical movement. No



correlation was found between the quality of the occlusion and the stability of the anteroposterior maxillary movement.

### Ethical approval

Obtained from the Greater Glasgow & Clyde Health Board (R&D reference: GN20OD634, REC reference: 21/NE/0019).

### Patient consent

Obtained.

### Funding

None.

### Author submission

All the authors viewed and agreed the submission.

### Competing interests

None.

### References

- Choi DS, Garagiola U, Kim SG. Current status of the surgery-first approach (part I): concepts and orthodontic protocols. *Maxillofac Plast Reconstr Surg* 2019; **41**:10.
- Jackson TH, Golden BA. Chapter 18: stability of orthognathic surgery. In: Naini FB, Gill DS, editors. *Orthognathic surgery: principles, planning and practice*. Wiley; 2016. p. 361–72.
- Peiro-Guijarro MA, Guijarro-Martinez R, Hernandez-Alfaro F. Surgery first in orthognathic surgery: a systematic review of the literature. *Am J Orthod Dentofacial Orthop* 2016; **149**:448–62.
- Yang L, Xiao Y, Liang Y, Wang X, Li J, Liao G. Does the surgery-first approach produce better outcomes in orthognathic surgery? A systematic review and meta-analysis. *J Oral Maxillofac Surg* 2017; **75**:2422–9.
- Nagasaka H, Sugawara J, Kawamura H, Nanda R. “Surgery first” skeletal Class III correction using the skeletal anchorage system. *J Clin Orthod* 2009; **43**:97–105.
- Liao YF, Chiu YT, Huang CS, Ko EWC, Chen YR. Presurgical orthodontics versus no presurgical orthodontics: treatment outcome of surgical-orthodontic correction for skeletal class III open bite. *Plast Reconstr Surg* 2010; **126**:2074–83.
- Liou EJW, Chen PH, Wang YC, Yu CC, Huang CS, Chen YR. Surgery-first accelerated orthognathic surgery: postoperative rapid orthodontic tooth movement. *J Oral Maxillofac Surg* 2011; **69**:781–5.
- Ko EWC, Hsu SSP, Hsieh HY, Wang YC, Huang CS, Chen YR. Comparison of progressive cephalometric changes and postsurgical stability of skeletal class III correction with and without presurgical orthodontic treatment. *J Oral Maxillofac Surg* 2011; **69**:1469–77.
- Lo SH, Chen YA, Yao CF, Liao YF, Chen YR. Is skeletal stability after bimaxillary surgery for skeletal class III deformity related to surgical occlusal contact? *Int J Oral Maxillofac Surg* 2019; **48**:1329–36.
- Soverina D, Gasparini G, Pelo S, Doneddu P, Todaro M, Boniello R, Azzuni C, Grippaudo C, Saponaro G, D’Amato G, Garagiola U, Moro A. Skeletal stability in orthognathic surgery with the surgery first approach: a systematic review. *Int J Oral Maxillofac Surg* 2019; **48**:930–40.
- Mulier D, Gaitán Romero L, Führer A, Martin C, Shujaat S, Shaheen E, Politis C, Jacobs R. Long-term dental stability after orthognathic surgery: a systematic review. *Eur J Orthod* 2021; **43**:104–12.
- Gaitán Romero L, Mulier D, Orhan K, Shujaat S, Shaheen E, Willems G, Politis C, Jacobs R. Evaluation of long-term hard tissue remodelling after skeletal class III orthognathic surgery: a systematic review. *Int J Oral Maxillofac Surg* 2020; **49**:51–61.
- Seifi M, Matini NS, Motabar AR, Motabar M. Dentoskeletal stability in conventional orthognathic surgery, presurgical orthodontic treatment and surgery-first approach in class-III patients. *World J Plast Surg* 2018; **7**:283–93.
- Choi JW, Lee JY, Yang SJ, Koh KS. The reliability of a surgery-first orthognathic approach without presurgical orthodontic treatment for skeletal class III dentofacial deformity. *Ann Plast Surg* 2015; **74**:333–41.
- Park KH, Sandor GK, Kim YD. Skeletal stability of surgery-first bimaxillary orthognathic surgery for skeletal class III malocclusion, using standardized criteria. *Int J Oral Maxillofac Surg* 2016; **45**:35–40.
- Choi SH, Yoo HJ, Lee JY, Jung YS, Choi JW, Lee KJ. Stability of pre-orthodontic orthognathic surgery depending on mandibular surgical techniques: SSRO vs IVRO. *J Craniomaxillofac Surg* 2016; **44**:1209–15.
- Ko EWC, Lin SC, Chen YR, Huang CS. Skeletal and dental variables related to the stability of orthognathic surgery in skeletal class III malocclusion with a surgery-first approach. *J Oral Maxillofac Surg* 2013; **71**:E215–23.
- Kim JY, Jung HD, Kim SY, Park HS, Jung YS. Postoperative stability for surgery-first approach using intraoral vertical ramus osteotomy: 12 month follow-up. *Br J Oral Maxillofac Surg* 2014; **52**:539–44.
- Mah DH, Kim SG, Oh JS, You JS, Jung SY, Kim WG, Yu KH. Comparative study of postoperative stability between conventional orthognathic surgery and a surgery-first orthognathic approach after bilateral sagittal split ramus osteotomy for skeletal class III correction. *J Korean Assoc Oral Maxillofac Surg* 2017; **43**:23–8.
- Park HM, Lee YK, Choi JY, Baek SH. Maxillary incisor inclination of skeletal Class III patients treated with extraction of the upper first premolars and two-jaw surgery: conventional orthognathic surgery vs surgery-first approach. *Angle Orthod* 2014; **84**:720–9.
- Zhou Y, Li Z, Wang X, Zou B, Zhou Y. Progressive changes in patients with skeletal Class III malocclusion treated by 2-jaw surgery with minimal and conventional presurgical orthodontics: a comparative study. *Am J Orthod Dentofacial Orthop* 2016; **149**:244–52.
- Park HM, Yang IH, Choi JY, Lee JH, Kim MJ, Baek SH. Postsurgical relapse in Class III patients treated with two-jaw surgery: conventional three stage method versus surgery-first approach. *J Craniofac Surg* 2015; **26**:2357–63.
- Ann HR, Jung YS, Lee KJ, Baik HS. Evaluation of stability after pre-orthodontic orthognathic surgery using cone-beam computed tomography: a comparison with conventional treatment. *Korean J Orthod* 2016; **46**:301–9.
- Lin CL, Chen YA, Yao CF, Chang CS, Liao YF, Chen YR. Comparative stability and outcomes of two surgical approaches for correction of class III asymmetry with lip or occlusal cant. *Clin Oral Invest* 2021; **25**:5449–62.
- Guo J, Wang T, Han JJ, Jung S, Kook MS, Park HJ, Oh HK. Corrective outcome and transverse stability after orthognathic surgery using a surgery-first approach in mandibular prognathism with and without facial asymmetry. *Oral Surg Oral Med Oral Pathol Oral Radiol* 2018; **126**:22–30.
- Liao YF, Atipatyakul P, Chen YH, Chen YA, Yao CF, Chen YR. Skeletal stability after bimaxillary surgery with surgery-first approach for class III asymmetry is not related to virtual surgical occlusal contact. *Clin Oral Invest* 2022; **26**:4935–45.
- Baek SH, Ahn HW, Kwon YH, Choi JY. Surgery-first approach in skeletal class III malocclusion treated with 2-jaw surgery: evaluation of surgical movement and postoperative orthodontic treatment. *J Craniofac Surg* 2010; **21**:332–8.
- Busby BR, Bailey LJ, Proffit WR, Phillips C, White Jr. RP. Long-term stability of surgical class III treatment: a

8 *Saghafi et al.*

- study of 5-year postsurgical results. *Int J Adult Orthodon Orthognath Surg* 2002; **17**:159–70.
29. Proffit WR, Turvey TA, Phillips C. The hierarchy of stability and predictability in orthognathic surgery with rigid fixation: an update and extension. *Head Face Med* 2007; **30**:21.
30. Fahradyan A, Wolfswinkel EM, Clarke N, Park S, Tsuha M, Urata MM, Hammoudeh JA, Yamashita DR. Impact of the distance of maxillary advancement on horizontal relapse after orthognathic surgery. *Cleft Palate Craniofac J* 2018; **55**:546–53.
31. Hernández-Alfaro F, Guijarro-Martínez R, Peiró-Guijarro MA. Surgery first in orthognathic surgery: what have we learned? A comprehensive workflow based on 45 consecutive cases. *J Oral Maxillofac Surg* 2014; **72**:376–90.
32. Baan F, Bruggink R, Nijsink J, Maal T, Ongkosuwito E. Fusion of intra-oral scans in cone-beam computed tomography scans. *Clin Oral Investig* 2021; **25**:77–85.
33. Anwar M, Benington PCM, Gillgrass TJ, Ayoub AF. Surgery-first approach for correction of class III dentofacial deformity with Le Fort I osteotomy; is it advantageous? *Br J Oral Maxillofac Surg* 2022; **60**:1234–9.
34. Saghafi H, Benington P, Ayoub A. Impact of orthognathic surgery on quality of life: a comparison between orthodontics-first and surgery-first approaches. *Br J Oral Maxillofac Surg* 2020; **58**:341–7.
35. AlOtaibi N, Liu C, Benington P, Ayoub A. Improvement in facial aesthetics of orthognathic patients after surgery-first approach. *Br J Oral Maxillofac Surg* 2023; **61**:666–71.

Correspondence to: Glasgow University  
Dental Hospital and School  
378 Sauchiehall Street  
Glasgow G2 3JZ  
United Kingdom.  
E-mail: ashraf.ayoub@glasgow.ac.uk