

CASE REPORT

Large fibrosarcoma of the equine distal limb treated by surgical excision using a harmonic scalpel

Nicholas A. Bellitto¹  | Mattie McMaster¹ | Ailidh Alvim² | Christian A. Byrne¹ 

¹Glasgow Equine Hospital & Practice,
School of Biodiversity, One Health
& Veterinary Medicine, University of
Glasgow, Glasgow, UK

²Forth Valley Vets, Falleninch Farm,
Stirling, UK

Correspondence: Nicholas A. Bellitto
Email: nicholas.alberto.bellitto@gmail.com

Summary

An 18-year-old Warmblood gelding was presented for investigation of a large, firm mass over the medial and plantar aspect of the left distal metatarsal and fetlock region. The mass was first identified 4 months prior to referral, following a traumatic incident, and had over time gradually increased in size. Clinical examination and diagnostic imaging revealed a large soft tissue mass adjacent to the metatarsophalangeal joint and digital flexor tendon sheath, with no overt involvement of underlying bone. The mass was surgically excised under general anaesthesia using a harmonic scalpel with limited margins to avoid compromise of adjacent anatomical structures. Following histology, the mass was diagnosed as a fibrosarcoma. Twelve months after surgical resection, no signs of recurrence were evident. This report demonstrates that fibrosarcoma of the equine distal limb may be successfully managed with surgical excision. The use of a harmonic scalpel should be considered as an alternative to sharp excision when treating fibrosarcoma or other infiltrative tumours, particularly those located in regions where only limited surgical margins may be achieved.

KEYWORDS

horse, distal limb swelling, fibrosarcoma, harmonic scalpel, surgical excision

INTRODUCTION

Equine fibrosarcoma is a spindle cell type soft tissue sarcoma and usually presents as a grey-white, firm, solitary, poorly demarcated and lobulated mass (Knottenbelt et al., 2015a; Liptak & Christensen, 2019). Equine fibrosarcoma has been reported to range between 3–25 cm in size and tends to infiltrate surrounding fascial planes, yet commonly also forms a pseudocapsule of compressed tumour cells (Bass et al., 2017; Hughes, 2007; Knottenbelt et al., 2015a, 2015b). It is a relatively uncommon tumour in horses, overall accounting for only 1.9% of all cutaneous and musculocutaneous neoplastic processes (Valentine, 2006). It may occur in horses of any age (Knottenbelt et al., 2015a) and has been described

in various locations including the distal limb (Bass et al., 2017; Findley et al., 2014; Story et al., 2005).

In all species, surgical excision with wide surgical margins, ideally of at least 3 cm, is the treatment of choice for fibrosarcoma because of its aggressive and invasive nature (Liptak & Christensen, 2019). However, wide excision may be impossible in certain regions and recurrence of disease has been reported to be common with conventional sharp surgical excision (Hughes, 2007; Knottenbelt et al., 2015a). Therefore, alternative forms of treatment or adjunctive treatments have been explored to reduce recurrence of fibrosarcoma in horses (Horbal & Dixon, 2016).

Harmonic scalpels are electromagnetic energy-based instruments which use ultrasonic energy for simultaneous tissue cutting

This is an open access article under the terms of the [Creative Commons Attribution-NonCommercial-NoDerivs](https://creativecommons.org/licenses/by-nc-nd/4.0/) License, which permits use and distribution in any medium, provided the original work is properly cited, the use is non-commercial and no modifications or adaptations are made.

© 2023 The Authors. *Equine Veterinary Education* published by John Wiley & Sons Ltd on behalf of EVJ Ltd.

and coagulation whilst operating at relatively low temperatures (Dubiel et al., 2010). This results in minimal collateral tissue damage, compared to some other ablative therapies such as electrocautery, therefore, harmonic scalpels have found application for treating tumours in human medicine (Cheng et al., 2018; Huang et al., 2015). This report describes successful treatment of a large mass with histological features of a fibrosarcoma in a horse, by surgical excision using a harmonic scalpel.

CASE DETAILS

History

An 18-year-old Warmblood gelding was referred for evaluation of a large, firm mass over the medial and plantar aspects of the left distal metatarsal and metatarsophalangeal region. The lesion was initially observed as a swelling that was not associated with an open wound. The swelling had developed following a traumatic incident during loading for transport in which the horse fell over and was stepped on by another horse.

Examination by the referring veterinary surgeon was performed 4 weeks after the traumatic incident due to a gradual enlargement of the swelling (Figure 1). The swelling was firm and moderately painful on palpation, but not associated with overt lameness, and was suspected to represent a soft tissue injury with a large, organising haematoma. Therefore, the gelding was treated with a prolonged course of non-steroidal anti-inflammatory drugs, cold hosing, and bandaging. There was limited response to treatment, with the mass gradually increasing in size. Consequently, 16 weeks following the traumatic incident the gelding was referred for further investigation.

Clinical findings

On presentation at the referral centre, the gelding was bright, alert and in good body condition. Vital parameters were within normal limits, and there was no significant lameness at walk. A large (widest circumference of 47 cm), firm, immobile swelling was present over the medial and plantar aspects of the distal metatarsal and metatarsophalangeal region of the left hindlimb which was firmly adhered to the underlying structures of the limb (Figure 2a,b). No palpable heat was detected and there was no overt pain on palpation. There were multiple areas of ulceration, likely due to interference with the contralateral limb. The gelding had a wide-based hindlimb action at walk, but this was symmetrical between the hindlimbs, with moderate hyper-extension of both hind fetlocks.

Radiographs of the left hind distal limb revealed a prominent soft tissue swelling which was not associated with any overt osseous abnormalities (Figure 2c,d). The metatarsophalangeal joint was moderately hyperextended (Figure 2c). On ultrasonographic examination, the mass was mainly confined to subcutaneous tissues and exhibited heterogeneous echogenicity. It was closely associated with the digital flexor tendon sheath, though the digital flexor tendons had a normal ultrasonographic appearance. Examination of other soft tissue structures of the limb (for example, the medial branch of the suspensory ligament) was limited by the presence of the mass.

Clinical examination and imaging findings were suggestive of a soft tissue mass, most likely composed of dense, yet poorly organised connective tissue. Options for further investigation such as magnetic resonance imaging and incisional biopsy were discussed, however, the owner opted to pursue surgical excision in the first instance.

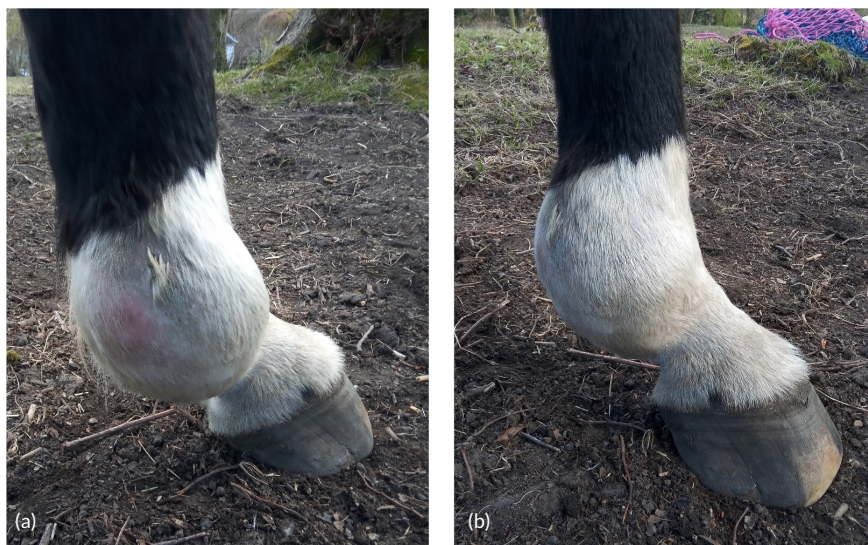

FIGURE 1 Photographs of the left hind distal limb swelling taken on initial examination by the referring veterinary surgeon (4 weeks after the traumatic incident).

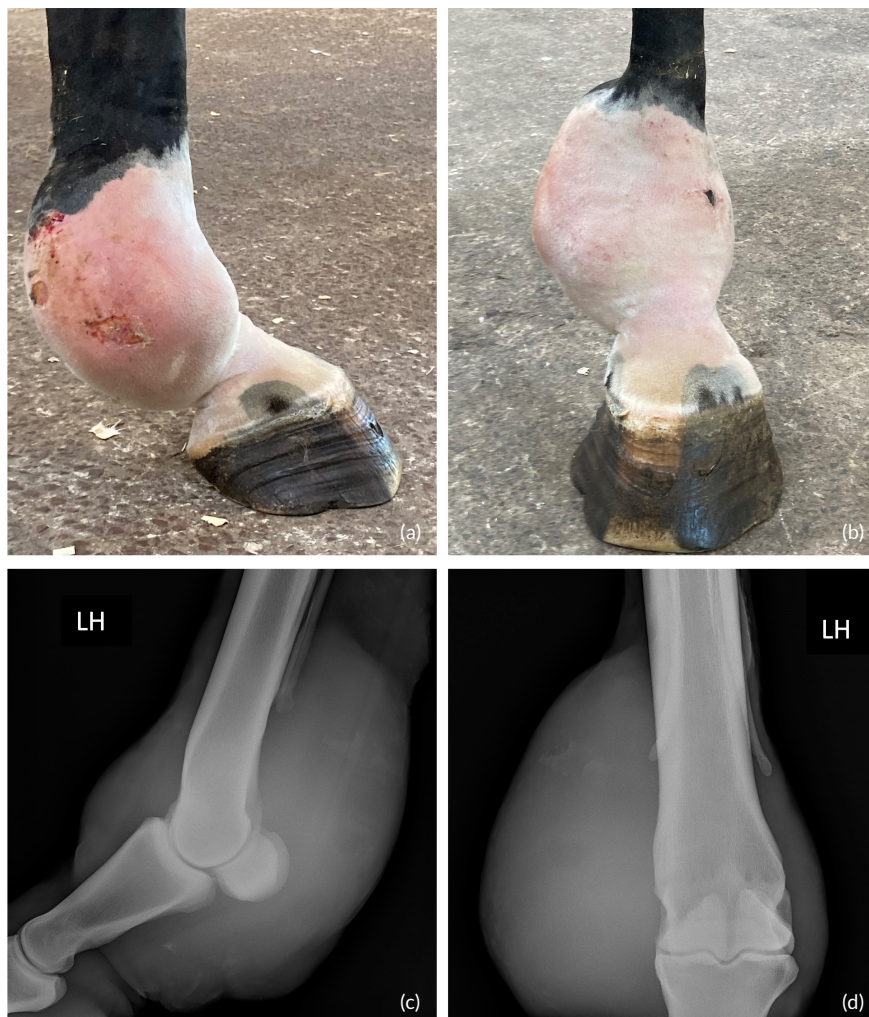


FIGURE 2 Photographs and radiographs of the left hind distal limb taken on presentation at the referral centre (16 weeks after the traumatic incident). (a and b) Photographs showing a large swelling with multiple ulcerations present over the medial and plantar aspect of the left distal metatarsal and metatarsophalangeal regions. (c) Lateromedial and (d) dorsoplantar radiographic views of left hind distal limb showing evidence of a plantar and medial prominent soft tissue swelling that is not associated with any overt osseous abnormalities.

Treatment and diagnosis

Procaine benzylpenicillin (20 mg/kg bwt i.m., q. 12h, Depocillin, MSD Animal Health), gentamicin (6.6 mg/kg bwt i.v., q. 24h Genta Equine, Dechra Veterinary Products) and flunixin meglumine (1.1 mg/kg bwt i.v., q. 12h, Meflosyl, Zoetis UK Ltd) were administered prior to and for 5 days after surgery. General anaesthesia was routinely induced using a combination of ketamine (2.2 mg/kg bwt i.v., Narketan, Vetoquinol) and midazolam (0.05 mg/kg bwt i.v. Dormazolam, Dechra Veterinary Products) and maintained with inhaled isoflurane (IsoFlo, Zoetis UK Ltd). Perioperative perineural blockade of the left medial and lateral plantar and plantar metatarsal nerves (high-four point), was performed using 10 mL of mepivacaine hydrochloride (2% w/v, Intra-Epicaine, Dechra Veterinary Products).

The gelding was placed in left lateral recumbency with the right hindlimb secured in a slightly flexed position to provide access to the medial aspect of the left hind distal limb (Figure 3a,b). The limb was routinely prepared and draped for surgery.

A 24 × 10 cm fusiform skin incision was made over the mass using a No. 10 blade, and the mass was dissected from the surrounding tissues using a harmonic scalpel (HARMONIC SYNERGY™ curved tip blade, Ethicon Endo Surgery LCC; Figure 3c). Device settings selected for the procedure were level 3 for minimum power (setting preferred for coagulation) and level 5 for maximum power (setting preferred for cutting).

The mass was firmly adhered to underlying tissues and in very close proximity to the digital flexor tendon sheath, medial suspensory ligament branch, metatarsophalangeal joint and third metatarsal bone.

It was not possible to safely establish a plane of dissection between the mass and surrounding soft tissues. The mass was initially excised incompletely. Residual portions of mass were subsequently excised in layers as extensively as possible (Figure 3d), however, ability to achieve clear visual margins of the mass was limited due to close association between the mass and the medial branch of the suspensory ligament and the flexor digital sheath and concern of

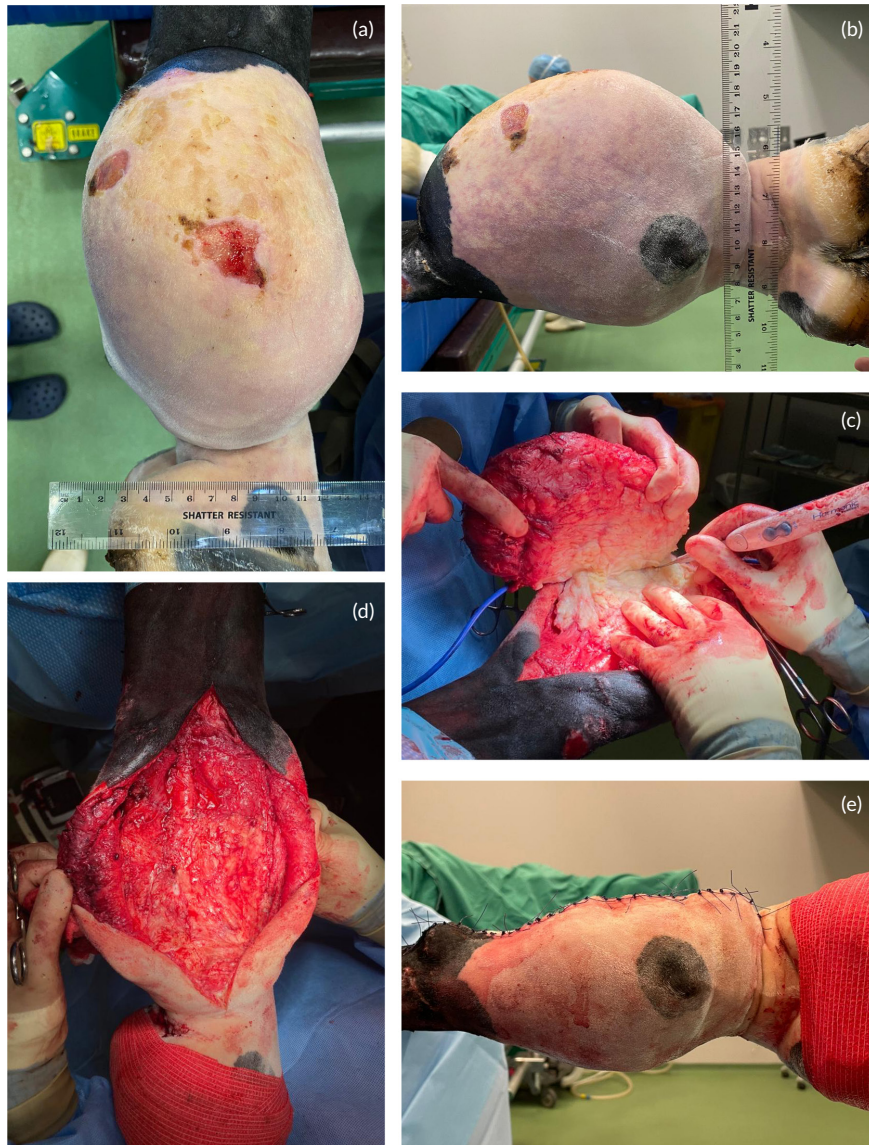

FIGURE 3 Intra-operative photographs. (a and b) Photographs of the large mass prior to surgical excision. (c) Photograph showing excision of the mass using a harmonic scalpel (HARMONIC SYNERGY™ curved tip blade, Johnson and Johnson International). (d) Photograph after excision of the mass. (e) Photograph following closure of the incision (three-layer closure).

iatrogenic damage to these structures. Minimal bleeding occurred during tissue dissection. After removal of the mass, the surgical site was lavaged and suctioned, and any excess skin at the wound edges was removed. Deeper layers of soft tissues and the subcutis were closed separately with a continuous suture pattern using No. 2-0 USP Polyglactin 910 (Vicryl, Johnson and Johnson International) and the skin was closed with a simple interrupted pattern using No. 2-0 USP Poliglecaprone 25 (Monocryl, Ethicon LCC; Figure 3e). A distal limb cast was applied to support the limb during recovery from anaesthesia as inadvertent iatrogenic damage to the suspensory apparatus could not be ruled out. The gelding had an uneventful rope-assisted recovery from anaesthesia.

The excised mass (dimensions: 185×118×72 mm) had a multilobular and disorganised fibrous tissue appearance with poorly

defined margins. Based on the location, clinical, histological and immunohistochemical features the mass was determined to represent a (likely low-grade) fibrosarcoma (Figure 4).

Five days after surgery the gelding was transitioned to trimethoprim sulphadiazine (30 mg/kg p.o. q. 12 h, Trimediazine Plain, Vetoquinol) for 24 days and suxibuzone (3.3 mg/kg bwt p.o. q. 24 h, Danilon, Elanco Animal Health) for 16 days. The cast was removed 2 days after surgery and replaced with a bandage. Five days following surgery, the gelding developed a seroma at the surgical site. Two simple interrupted skin sutures were removed to drain a moderate amount of serohaemorrhagic discharge by active compression. The half-limb bandage was maintained for 7 weeks (changed at 24–76 h intervals) and serohaemorrhagic discharge from the surgical wound gradually decreased and ceased 5 weeks

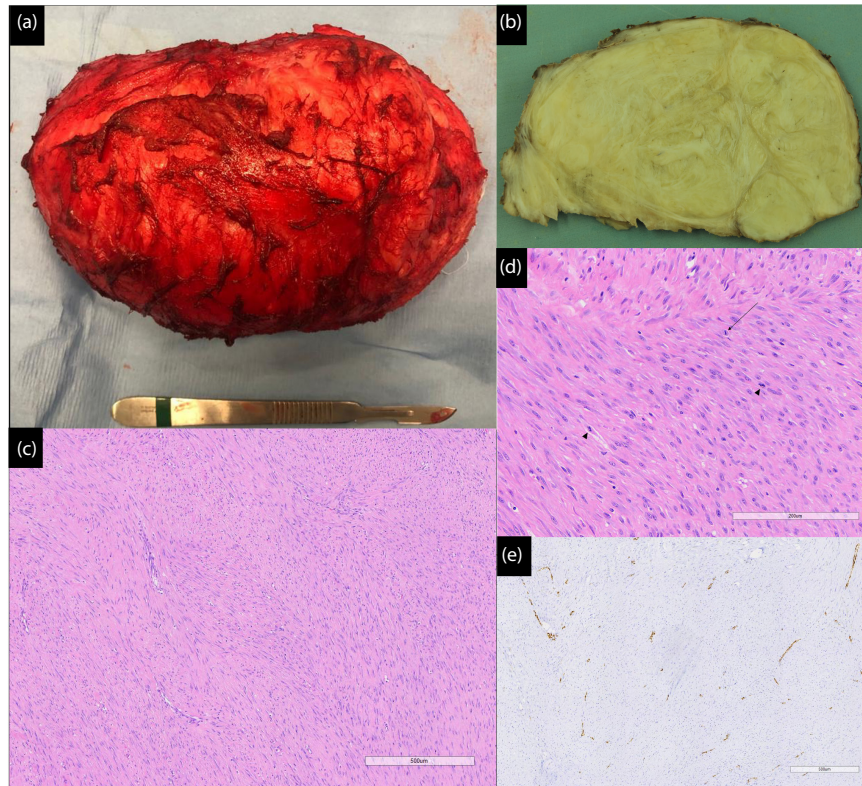


FIGURE 4 Photograph and photomicrographs of the mass excised from the left distal hindlimb (a) Photograph of the most superficial portion of the excised mass (underlying the subcutaneous tissues) with a pseudocapsule appearance and dimensions of $185 \times 118 \times 72$ mm. (b) Photograph of a cross section of the excised mass following fixation in formalin showing a multilobular and disorganised fibrous tissue appearance. (c) Overview of the mass with neoplastic spindle cells arranged in intercalating, haphazardly arranged streams and bundles. (d) High-power magnification of neoplastic population exhibiting small numbers of mitotic figures (arrow) including atypical forms (arrowheads). (e) Immunohistochemistry staining for smooth muscle Actin indicating that the vast majority of the neoplastic population lack a stain for smooth muscle Actin (tunica media cells of small vessels act as an internal positive control).

after surgery. The gelding was discharged from hospital 6 weeks after surgery. Following this, the gelding gradually resumed full-time turn out.

Outcome

The gelding was reassessed at 5, 9 and 12 months following surgical treatment. On all three occasions, there was mild residual swelling of the medial aspect of the left hind metatarsophalangeal region, which was unchanged when compared to the day of discharge from the hospital (Figure 5a,b). Overall, the left and right hind metatarsophalangeal regions were comparable in size. The gelding did not resent palpation or flexion of the region and there was no significant lameness at walk. Ultrasonographic and radiographic evaluation, at the 9-month reassessment, revealed moderate thickening of soft tissues in the region, however, recurrence of the neoplastic process was not evident (Figure 5c,d). There were no systemic clinical signs (e.g. weight loss or respiratory difficulty) or any enlargement of regional lymph nodes to suggest metastatic disease. The owner reported satisfactory progress with the

gelding having returned to its previous level of ridden work, which consisted exclusively of walking and trotting exercise, at 8 months post-surgery.

DISCUSSION

Clinical presentation, diagnosis and treatment of fibrosarcoma

The gelding described in this case report developed a distal limb swelling, which subsequently was diagnosed to be consistent with a fibrosarcoma. The mass was found to be localised within the subcutaneous layers with no gross evidence of direct infiltration of the ligamentous, tendinous or synovial structures that were in close proximity.

Focal distal limb swelling is a common presentation in horses, though neoplastic disease only represents a small proportion of such cases. Both in dogs and humans, trauma and scar tissue have been implicated in the formation of soft tissue sarcoma (Kabir & Choong, 2021; Liptak & Christensen, 2019), whilst equine

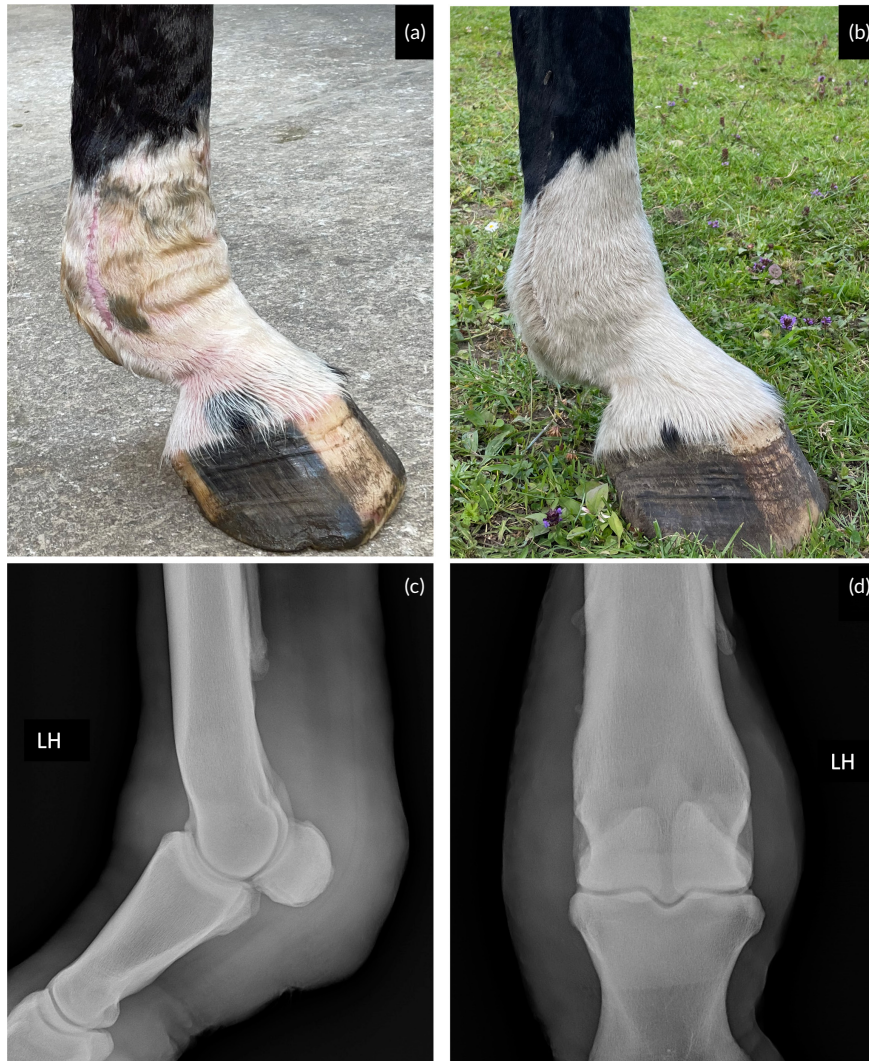

FIGURE 5 Photographs and radiographs of the left hind distal limb taken on reassessment by the referral centre. (a) Photograph taken at 9-month reassessment showing an incisional scar and minimal residual swelling present over the medial aspect of the left distal hindlimb at the level of the surgical site. (b) Photograph taken at 12-month reassessment showing similar findings to those observed at the 9-month reassessment. (c) Lateromedial and (d) dorsoplantar radiographs of left hind distal limb taken at 9-month reassessment showing evidence of minimal residual swelling on the plantar and medial aspect of the distal limb where the mass was previously excised.

fibrosarcoma specifically has been reported to be associated with vaccine-injection (Kannegieter et al., 2010) and burn injury (Schumacher et al., 1986). In this case, it is possible that the fibrosarcoma developed following the traumatic incident, whether trauma promoted growth of a pre-existing lesion, or whether the tumour was unrelated to trauma. Hyper-extension of the left metatarsophalangeal joint was detected on clinical examination; however, this was comparable with the right metatarsophalangeal joint and was reported by the owner to have been present prior to the injury, making this finding unlikely related to the fibrosarcoma. Differentiation of neoplastic processes such as sarcoid and fibrosarcoma from other lesions such as hyperplastic granulation tissue can be challenging (Findley et al., 2014; Hughes, 2007). Given the history of trauma in this case, nodular fasciitis, a reactive (self-limiting) lesion that occurs due to trauma, as described in dogs and humans, was also considered. However, the lack of

haemorrhage and relative paucity of inflammation on histological examination did not support this diagnosis. Similarly, the cellularity was considered to be inconsistent with a fibroma and the lack of involvement of skeletal muscle ruled out the presence of fibromatosis. The use of cytology for the diagnosis of fibrosarcoma is often of limited value, with samples often being non-diagnostic or not permitting differentiation from other pathologies (Cohen et al., 2003; Hughes, 2007), and, thus, the diagnosis of fibrosarcoma in horses is largely based on histopathological morphology (Knottenbelt et al., 2015a; Liptak & Christensen, 2019; Story et al., 2005). Other forms of soft tissue sarcomas that have been reported affecting the distal limbs in horses include a malignant fibrous histiocytoma (Geburek et al., 2007) and a myofibroblastic sarcoma (Silva et al., 2012). Histopathology may be performed on biopsy samples or following complete mass excision. Biopsy of a mass is strongly advised if the outcome of the histological findings

is likely to alter the approach and management of the case. Biopsy is not recommended if it is not going to alter the management of the tumour or help the owner to decide about treatment options (Knottenbelt et al., 2015c). When taking a biopsy sample, size and location should be carefully considered. If samples are small, poorly oriented or fragmented, this may cause increased difficulty in histological differentiation between fibrosarcoma and hyperplastic granulation tissue, fibrous dysplasia or other tumours (Findley et al., 2014).

In the gelding described in this report, surgical excision of the mass with submission for histopathology was elected as the treatment of choice, following discussion with the owner.

The decision to not take a pre-operative biopsy was made on the basis that surgical excision would most likely have been required to avoid any further trauma to the mass from the contralateral limb and that the owner wished to attempt surgical excision regardless of any information on prognosis that could have been provided by pre-operative histopathology. Recurrence of disease following excision of fibrosarcoma in horses is reported to be common, likely because of inadequate surgical margins or contamination of tissues with neoplastic cells, termed 'seeding' (Hughes, 2007; Knottenbelt et al., 2015a). Due to the challenges of treating fibrosarcoma in horses, other treatments have been used alone or in combination with surgery to improve outcomes, however the value of adjunctive therapies such as radiation and chemotherapeutics in the treatment of fibrosarcoma reportedly can vary due to the slow metabolic rate of some lesions (Augsburger et al., 2017; Bass et al., 2017; Ngan et al., 2021).

After having received the histopathology results, chemotherapy and radiotherapy treatments were discussed with the owner. Taking into consideration the potential benefits and relative costs, the owner elected to not pursue either of these treatments. Reported adjuncts to surgical excision of equine fibrosarcoma of various sites include intralesional injection with cisplatin (Horbal & Dixon, 2016), electrochemotherapy with intralesional or perilesional cisplatin injection (Spugnini et al., 2016, 2021), topical 5-fluorouracil (Roels et al., 1998) and implantation of cisplatin-containing biodegradable beads (Hewes & Sullins, 2006). Challenges of treatment comparisons include the sparsity of reports and differences in methods utilised to establish a diagnosis of a fibrosarcoma.

Harmonic scalpel

In this case, a large distal limb fibrosarcoma was treated through excision by ultrasonic dissection using a harmonic scalpel (HARMONIC SYNERGY™ curved tip blade, Ethicon Endo Surgery LCC), for which various blades are available that can be utilised in open or laparoscopic surgery. Electromagnetic energy is produced from a generator and is then converted into high-frequency ultrasonic mechanical energy by a transducer within the handpiece. This ultrasonic mechanical energy is then delivered, through a titanium shaft, to the blade. Activation of the blade will result in high frequency vibrations (55,500 cycles/s) of the tip of the blade with a longitudinal blade displacement that varies

between 50 and 100µm according to the settings selected (Dubiel et al., 2010). Coagulation occurs following blade interaction with the tissue and disruption of protein hydrogen bonds while cutting is achieved by cavitation fragmentation and mechanical vibration. Variation in pressure applied by the surgeon allows control of cutting speed and degree of coagulation (Dubiel et al., 2010).

Systemic reviews and meta-analyses in human medicine report that the use of harmonic scalpels, when compared to other ablative therapies, results in a significant reduction in operating time, postoperative drainage, seroma development and intraoperative blood loss (Cheng et al., 2015, 2018; Dubiel et al., 2010; Huang et al., 2015). A further significant advantage of using harmonic scalpels is the reduced amount of viable airborne neoplastic cells released during excision when compared to sharp dissection (Hashimoto et al., 2017; Nduka et al., 1998).

In veterinary medicine, the use of harmonic scalpels has been reported for various laparoscopic procedures (Hancock et al., 2005; Khalaj et al., 2012; Mayhew et al., 2008; Risselada et al., 2010a, 2010b; Vasanjee et al., 2006), for soft palate resection in dogs (Michelsen, 2011) and in horses for laparoscopic ovariectomy, ovari-hysterectomy, and thyroidectomy (al Naem et al., 2022; Delling et al., 2004; Dusterdieck et al., 2003).

This case report documents the use of a harmonic scalpel in the treatment of distal limb equine neoplasia, highlighting that this instrument may represent a useful alternative for surgical management of fibrosarcoma in horses. The 12-month follow-up period did not demonstrate (gross) recurrence of this mass; however, it is possible that recurrence of the tumour may take longer than 12 months and further follow-up would be desirable to determine longer term outcome.

CONCLUSION

To the authors' knowledge, this is the first report describing successful treatment of an equine fibrosarcoma in the distal metatarsal and metatarsophalangeal regions by use of a harmonic scalpel for surgical excision of the mass. Furthermore, it highlights that a harmonic scalpel may be particularly useful in regions where the extent of excision is limited or where minimisation of collateral tissue damage is essential.

AUTHOR CONTRIBUTIONS

The case was diagnosed and treated pre-operatively by A. Alvim. C.A. Byrne, M. McMaster and N. A. Bellitto performed surgery. A. Alvim, C.A. Byrne, M. McMaster and N.A. Bellitto were responsible for post-operative care and follow-up reassessments. N.A. Bellitto primarily prepared the manuscript. C.A. Byrne supervised preparation of the manuscript. All authors contributed to and gave their final approval of the manuscript.

ACKNOWLEDGEMENTS

The authors wish to thank Angie Rupp (Senior Veterinary Clinician in the Division of Pathology, Public Health and Disease Investigation

at the School of Veterinary Medicine, University of Glasgow) for assisting with this case and for kindly providing the gross and histology images. The authors would also like to thank all the staff and students of Glasgow Equine Hospital & Practice for their assistance with the care of this case.

CONFLICT OF INTEREST STATEMENT

No conflicts of interest have been declared.

ETHICS STATEMENT

Consent was gained from the owner for all clinical procedures and for the use of case material for teaching and publication purposes. Ethical approval is not required for this retrospective case report.

ORCID

Nicholas A. Bellitto  <https://orcid.org/0000-0003-4526-9831>

Christian A. Byrne  <https://orcid.org/0000-0003-0798-0286>

REFERENCES

- al Naem, M., Litzke, L.F. & Mourad, A.A.G. (2022) Thyroidectomy facilitated with harmonic caliper and intraoperative neural monitoring in three horses. *Equine Veterinary Education*, 35(1), e45–e51.
- Augsburger, D., Nelson, P.J., Kalinski, T., Udelnow, A., Knösel, T., Hofstetter, M. et al. (2017) Current diagnostics and treatment of fibrosarcoma - perspectives for future therapeutic targets and strategies. *Oncotarget*, 8(61), 104638–104653.
- Bass, K., Mochal-King, C.A., Cooley, A.J. & Brinkman, E. (2017) Equine mandibular fibrosarcoma in two horses: clinical, diagnostic, and therapeutic considerations. *Journal of Equine Veterinary Science*, 48, 31–38.
- Cheng, H., Clymer, J.W., Sadeghirad, B., Ferko, N.C., Cameron, C.G. & Amaral, J.F. (2018) Performance of harmonic devices in surgical oncology: an umbrella review of the evidence. *World Journal of Surgical Oncology*, 16(1), 2.
- Cheng, H., Hsiao, C.W., Clymer, J.W., Schwiens, M.L., Tibensky, B.N., Patel, L. et al. (2015) Gastrectomy and D2 lymphadenectomy for gastric cancer: a meta-analysis comparing the harmonic scalpel to conventional techniques. *International Journal of Surgical Oncology*, 2015, 397260.
- Cohen, M., Bohling, M.W., Wright, J.C., Welles, E.A. & Spano, J.S. (2003) Evaluation of sensitivity and specificity of cytologic examination: 269 cases (1999–2000). *Journal of the American Veterinary Medical Association*, 222, 964–967.
- Delling, U., Howard, R.D., Pleasant, R.S. & Lanz, O.I. (2004) Hand-assisted laparoscopic ovariectomy in the Mare. *Veterinary Surgery*, 33, 487–494.
- Dubiel, B., Shires, P.K., Korvick, D. & Chekan, E.G. (2010) Electromagnetic energy sources in surgery. *Veterinary Surgery*, 39(8), 909–924.
- Düsterdieck, K.F., Pleasant, R.S., Lanz, O.I., Saunders, G. & Howard, R.D. (2003) Evaluation of the harmonic scalpel for laparoscopic bilateral ovariectomy in standing horses. *Veterinary Surgery*, 32, 242–250.
- Findley, J.A., Singer, E.R., Milner, P.I. & Leeming, G.H. (2014) Use of immunohistochemical staining and electron microscopy to aid in diagnosis of soft tissue sarcomas associated with the fetlock joint in two horses. *Journal of Veterinary Diagnostic Investigation*, 26, 465–469.
- Geburek, F., van Oppen, T., Hewicker-Trautwein, M. & Ohnesorge, B. (2007) Diagnosis and therapy of a malignant fibrous histiocytoma on the forelimb of a quarter horse mare. *Equine Veterinary Education*, 18, 19–22.
- Hancock, R.B., Lanz, O.I., Waldron, D.R., Duncan, R.B., Broadstone, R.V. & Hendrix, P.K. (2005) Comparison of postoperative pain after ovariohysterectomy by harmonic scalpel-assisted laparoscopy compared with median celiotomy and ligation in dogs. *Veterinary Surgery*, 34, 273–282.
- Hashimoto, M., Kobayashi, T., Tashiro, H., Kuroda, S., Mikuriya, Y., Abe, T. et al. (2017) Viability of airborne tumor cells during excision by ultrasonic device. *Surgery Research and Practice*, 2017, 1–5.
- Hewes, C.A. & Sullins, K.E. (2006) Use of cisplatin-containing biodegradable beads for treatment of cutaneous neoplasia in equidae: 59 cases (2000–2004). *Journal of the American Veterinary Medical Association*, 229, 1617–1622.
- Horbal, A. & Dixon, P.M. (2016) Gingival fibrosarcoma in a horse: a case report. *Journal of Veterinary Dentistry*, 33, 243–248.
- Huang, J., Yu, Y., Wei, C., Qin, Q., Mo, Q. & Yang, W. (2015) Harmonic scalpel versus electrocautery dissection in modified radical mastectomy for breast cancer: a meta-analysis. *PLoS One*, 10(11), e0142271.
- Hughes, K.J. (2007) Soft tissue sarcomas in the horse. *Equine Veterinary Education*, 19, 23–24.
- Kabir, W. & Choong, P.F.M. (2021) The epidemiology and pathogenesis of sarcoma. In: Choong, P. F. M. (Ed.) *Sarcoma*. Singapore: Springer, pp. 11–27.
- Kannegieter, N.J., Schaaf, K.L., Lovell, D.K., Simon, C.D. & Stone, B.M. (2010) Myofibroblastic fibrosarcoma with multifocal osseous metaplasia at the site of equine influenza vaccination. *Australian Veterinary Journal*, 88, 132–136.
- Khalaj, A., Bakhtiari, J. & Niasari-Naslaji, A. (2012) Comparison between single and three portal laparoscopic splenectomy in dogs. *BMC Veterinary Research*, 8, 161.
- Knottenbelt, D.C., Patterson-Kane, J.C. & Snalune, K.L. (2015a) Mesenchymal neoplasms: fibrous and adipose. In: Knottenbelt, D. C., Patterson-Kane, J. C. & Snalune, K. L. (Eds.) *Clinical Equine Oncology*. Edinburgh: Elsevier, pp. 285–298.
- Knottenbelt, D.C., Patterson-Kane, J.C. & Snalune, K.L. (2015b) Tumours of the skin. In: Knottenbelt, D. C., Patterson-Kane, J. C. & Snalune, K. L. (Eds.) *Clinical Equine Oncology*. Edinburgh: Elsevier, pp. 544–584.
- Knottenbelt, D.C., Patterson-Kane, J.C. & Snalune, K.L. (2015c) Principles of oncological therapies. In: Knottenbelt, D. C., Patterson-Kane, J. C. & Snalune, K. L. (Eds.) *Clinical Equine Oncology*. Edinburgh: Elsevier, pp. 118–197.
- Liptak, J.M. & Christensen, N.I. (2019) Soft tissue sarcomas. In: *Withrow and MacEwen's Small Animal Clinical Oncology*. St. Louis, MO: Saunders Elsevier, pp. 404–431.
- Mayhew, P.D., Mehler, S.J. & Radhakrishnan, A. (2008) Laparoscopic cholecystectomy for Management of Uncomplicated Gall Bladder Mucocele in six dogs. *Veterinary Surgery*, 37, 625–630.
- Michelsen, J. (2011) Use of the harmonic scalpel for soft palate resection in dogs: a series of three cases. *Australian Veterinary Journal*, 89, 511–514.
- Nduka, C.C., Poland, N., Kennedy, M., Dye, J. & Darzi, A. (1998) Does the ultrasonically activated scalpel release viable airborne cancer cells? *Surgical Endoscopy*, 12(8), 1031–1034.
- Ngan, S.Y., Chu, J. & Chander, S. (2021) The role of radiotherapy for sarcoma. In: *Sarcoma*. Singapore: Springer, pp. 153–168.
- Risselada, M., Ellison, G.W., Bacon, N.J., Polyak, M.M.R., van Gilder, J., Kirkby, K. et al. (2010a) Comparison of 5 surgical techniques for partial liver lobectomy in the dog for intraoperative blood loss and surgical time. *Veterinary Surgery*, 39, 856–862.
- Risselada, M., Polyak, M.M.R., Ellison, G.W., Bacon, N.J., van Gilder, J.M., Coomer, A.R. et al. (2010b) Postmortem evaluation of surgery site leakage by use of in situ isolated pulsatile perfusion after partial liver lobectomy in dogs. *American Journal of Veterinary Research*, 71, 262–267.

- Roels, S., Ducatelle, R., van De Vijver, B. & de Kruif, A. (1998) Successful treatment of an equine preputial fibrosarcoma using 5-fluorouracil/evaluation of the treatment using quantitative PCNA and K167 (MIB 1) immunostaining (case report). *Journal of the Veterinary Medical Association*, 45, 591–598.
- Schumacher, J., Watkins, J.P., Wilson, S.R. & Foreman, M.E. (1986) Burn-induced neoplasia in two horses. *Equine Veterinary Journal*, 18, 410–412.
- Silva, J.F., Palhares, M.S., Maranhão, R.P., Gheller, V.A., Boeloni, J.N., Serakides, R. et al. (2012) Myofibroblastic sarcoma in the limb of a horse. *Journal of Equine Veterinary Science*, 32, 197–200.
- Spugnini, E.P., Bolaffio, C., Scacco, L. & Baldi, A. (2016) Electrochemotherapy increases local control after incomplete excision of a recurring penile fibrosarcoma. *Open Veterinary Journal (Tripoli, Libya)*, 6, 234–237.
- Spugnini, E.P., Scacco, L., Bolaffio, C. & Baldi, A. (2021) Electrochemotherapy for the treatment of cutaneous solid tumors in equids: a retrospective study. *Open Veterinary Journal*, 11, 385–389.
- Story, M.R., Gaughan, E.M., Andrews, G.A. & Balch, S. (2005) Fibrosarcoma over the tarsal groove of a 14-month-old quarter horse. *Veterinary and Comparative Orthopaedics and Traumatology*, 18, 115–118.
- Valentine, B.A. (2006) Survey of equine cutaneous neoplasia in the Pacific northwest. *Journal of Veterinary Diagnostic Investigation*, 18, 123–126.
- Vasanjee, S.C., Bubenik, L.J., Hosgood, G. & Bauer, R. (2006) Evaluation of hemorrhage, sample size, and collateral damage for five hepatic biopsy methods in dogs. *Veterinary Surgery*, 35, 86–93.

How to cite this article: Bellitto, N.A., McMaster, M., Alvim, A. & Byrne, C.A. (2023) Large fibrosarcoma of the equine distal limb treated by surgical excision using a harmonic scalpel. *Equine Veterinary Education*, 35, e620–e628.

Available from: <https://doi.org/10.1111/eve.13808>