



Chalfon, C. et al. (2023) Patterns of nodal metastases, biological behavior and prognosis of canine mast cell tumors of the pinna: a multi-institutional retrospective study. *Veterinary and Comparative Oncology*, 21(2), p. 332. (doi: [10.1111/vco.12893](https://doi.org/10.1111/vco.12893))

This is the author version of the work. You are advised to consult the publisher version if you wish to cite from it:

<https://doi.org/10.1111/vco.12893>

<https://eprints.gla.ac.uk/294777/>

Deposited on: 29 March 2023

Enlighten – Research publications by members of the University of Glasgow
<http://eprints.gla.ac.uk>

1 **Patterns of nodal metastases, biological behavior and prognosis of canine mast cell**
2 **tumors of the pinna: a multi-institutional retrospective study**

3 Chalfon Carmit¹, Finotello Riccardo², Sabattini Silvia¹, Gramer Irina³, Morris Joanna⁴, Aralla Marina⁵,
4 Morello Maria Emanuela⁶, Ferraris Erica⁶, Ramos Sofia⁷, Polton Gerry⁷, Schiavo Luca⁸, Dobson Jane⁸,
5 Cola Veronica¹, Marconato Laura¹

6
7 1 Department of Veterinary Medical Sciences, University of Bologna, Ozzano dell'Emilia, Italy

8 2 Department of Small Animal Clinical Science, School of Veterinary Science, Institute of Infection, Veterinary and Ecological
9 Sciences, University of Liverpool, Neston, United Kingdom

10 3 Department of Clinical Science and Services, Royal Veterinary College, United Kingdom

11 4 Department of Small Animal Clinical Sciences, School of Veterinary Medicine, College of Medical, Veterinary and Life
12 Sciences, University of Glasgow, Glasgow, United Kingdom

13 5 Pronto Soccorso Veterinario Laudense, Lodi, Italy

14 6 Department of Veterinary Sciences, University of Turin, Grugliasco, Italy

15 7 North Downs Specialist Referrals, Bletchingley, United Kingdom

16 8 Department of Veterinary Medicine, Cambridge Veterinary School, University of Cambridge, Cambridge, United Kingdom

17
18 Carmit Chalfon's current address is Centro Veterinario Torinese, Turin, 10153, Italy.

19 Riccardo Finotello's current address is Department of Veterinary Medicine, University of Bari,
20 Valenzano, 70010, Italy

21 Irina Gramer's current address is Southpaw, 3 Roper street, Moorabbin 3189, Victoria, Australia.

22 Luca Schiavo's current address is Davies Veterinary Specialists, Manor Farm Business Park, Higham
23 Gobion, Hitchin SG5 3HR.

24
25 Corresponding author: Carmit Chalfon

26 Email: carmit_yam@hotmail.com

27 ORCID: 0000-0002-3062-4303

28 Acknowledgments: authors would like to thank all the clinicians who contributed to case recruitment

29
30 **Conflict of interest statement**

31 The authors do not have any potential conflicts of interest to declare

32
33 **Abstract**

34 Canine cutaneous mast cell tumors (cMCTs) of the pinna have been associated with an aggressive
35 biological behavior, although data remain scarce. The knowledge acquired over the past years on
36 histologic gradings, and the value of lymph node (LN) staging, may help in better characterizing this
37 anatomical presentation.

38 The first aim was to describe the frequency, location, and histologic appearance of LN metastases in
39 cMCT of the pinna. A second aim was to evaluate prognosis.

40 Medical records of dogs with cMCT of the pinna, that underwent tumor and sentinel (SLN) or regional
41 LN (RLN) excision, were reviewed. The influence of potential prognostic variables on time to progression
42 (TTP) and tumor-specific survival (TSS) was investigated.

43 Thirty-nine dogs were included: 19 (48.7%) had Kiupel high-grade (K-HG) and 20 (51.3%) had low-
44 grade (K-LG) MCTs. Eighteen (46.1%) dogs underwent SLN mapping; the superficial cervical LN was
45 at least one of SLN in 17 (94.4%) cases.

46 Twenty-two (56.4%) dogs had LN metastases; the superficial cervical LN was always involved.

47 On multivariable analysis, only K-HG was associated with increased risk of progression ($p=0.043$) and
48 tumor-related death ($p=0.021$). Median TTP and TSS were 270 and 370 days in K-HG, respectively; these
49 were not reached in dogs with K-LG tumors ($p<0.01$).

50 cMCTs of the pinna are often K-HG and are also associated with a higher frequency of LN metastasis;
51 however, we confirmed the independent prognostic value of histologic grading. A multimodal treatment
52 may lead to favorable long-term outcome. Moreover, the superficial cervical LN is most often the SLN.

53
54 Keywords: dog, pinnal, mastocytoma, nodal, metastasis, outcome

55
56 Acknowledgments: authors would like to thank all the clinicians who contributed to case recruitment
57

58 **Conflict of interest statement**

59 The authors do not have any potential conflicts of interest to declare
60

61 Word count:3495
62
63

Introduction

The biological behavior of canine cutaneous mast cell tumors (cMCT) is variable. Tumors exhibit a range of malignancy, with higher-grade tumors carrying a high risk for recurrence and metastasis.¹⁻⁴

Anatomic location has been proposed as a simple predictor of aggressive behavior, with inguinal, perineal and orofacial sites being the most frequently cited.^{1,2,3,5-10}

Biologic behavior is predicted more broadly by histologic grade and lymph node (LN) status, independent of the site of origin.^{3,7,8,11,12} But, an association between high tumor grade and inguinal, axillary or scrotal location does exist, with Kiupel high-grade (K-HG) cMCT representing 73.3%, 63.6% and 57.1% of the samples, respectively.¹¹ These numbers contrast with the overall prevalence of K-HG designation among cMCTs, which tends not to exceed 20%.¹³ cMCT located on the muzzle have also been reported to exhibit a higher risk of LN metastasis when compared to other cutaneous sites, occurring in 58% of cases.³

Focusing on pinnal cMCT, Schwab and colleagues reported a percentage of Patnaik grade III (P-GIII) cMCT twice greater than Patnaik grade I (P-GI cMCT; 28.6% vs 14.3%, respectively), while in more than 50% of cases the primary cMCT was histologically classified as Patnaik grade II (P-GII). Dogs with P-GIII cMCT of the pinna had significantly shorter survival when compared to dogs with P-GI or P-GII cMCT (10 months vs not reached, respectively). LN metastases at the time of diagnosis were not identified in any of the dogs, but LN assessment was not performed in most (92.8%) cases.¹² Overall, data on pinnal cMCT remain scarce and outdated when considering the knowledge acquired over the past years on histologic tumor and LN gradings, and the value of LN staging.^{10,12,14-17}

According to the World Health Organization (WHO) clinical staging system, stage II cMCT is defined as a primary single tumor confined to the dermis with regional LN (RLN) metastasis.¹⁸ Standardized histologic criteria have been proposed to more consistently characterize nodal involvement, and 4 histologic patterns have been identified: HN0, non-metastatic LN; HN1, pre-metastatic LN; HN2, early metastasis and HN3, overt metastasis.¹⁹

Based on anatomic studies, most of the lymph vessels of the pinna drain to the superficial cervical LN. A small number drain to the lateral retropharyngeal and medial retropharyngeal LNs, as well as to the parotid LN.¹²⁻²² The sentinel lymph node (SLN) is defined as the first LN receiving drainage from a primary tumor and is expected to be the first site of metastasis. Recent studies suggest that SLN and RLN do not match in 28-63% of cases, highlighting the importance of SLN mapping during the staging work-up.^{14,17,23} However, there are no reports specifically describing the patterns of nodal metastases of pinnal cMCTs.

Hence, the first aim of this multi-institutional retrospective study was to describe the frequency, location and histologic stage of nodal metastases among dogs with cMCT of the pinna that underwent concurrent lymphadenectomy. The second aim was to evaluate prognosis.

Materials and Methods

Study design and inclusion criteria:

01 Medical records of eight (University of Bologna [n= 14 cases], University of Liverpool [n=8 cases],
02 Royal Veterinary College [n=6 cases], Pronto Soccorso Veterinario Laudense [n=3 cases], University of
03 Glasgow [n=2 cases], University of Turin [n=2 cases], North Downs Specialist referrals[n=2 cases],
04 University of Cambridge [n=2 cases]) institutions were retrospectively reviewed to identify dogs with a
05 single, treatment-naïve cMCT of the pinna that underwent surgical excision of the primary tumor and
06 concurrent lymphadenectomy of SLN/s or RLN/s. To be eligible for inclusion, dogs had to undergo a
07 staging work-up, including hematologic and biochemical analysis, thoracic imaging (radiography or
08 computed tomography; CT), abdominal ultrasound and fine-needle aspiration of liver and spleen. Data of
09 additional tests (e.g., sentinel LN mapping, cytologic evaluation of RLN vs SLN, CT-total body) were
10 collected, if available, for review.

11 Dogs with multiple head and neck MCTs at the time of diagnosis were excluded from the analysis.

12 Among dogs that underwent SLN mapping, SLNs were identified pre-operatively by means of CT-
13 lymphangiography, using peritumoral administration of water-soluble iodine-based contrast agents, as
14 previously reported.²⁴ We considered the SLN to be the first LN/s (station 1 nodes) receiving contrast
15 from neoplastic lesion, by the same or different lymphatic pathways. All other nodes were presumed to
16 be afflicted subsequently and were not included in the analysis.^{24,25}

17 The primary tumor was graded into Kiupel low-grade (K-LG) and K-HG.²⁶ All LNs were classified
18 according to Weishaar criteria.¹⁹ Primary MCTs and LNs were evaluated by multiple pathologists and
19 slides were not available for review.

20 Data on adjuvant medical oncologic treatments were retrieved from the records; additional medical
21 therapies were allowed and recorded.

22 For each case the following data were recorded: signalment (breed, age, sex and weight), clinical substage
23 (i.e., asymptomatic [a] or symptomatic [b]), primary tumor description (presence of ulceration, largest
24 diameter, location [right or left pinnae]), SLN-mapping (yes or no), SLN location, number of SLN/s or
25 RLN/s removed, LN status (HN0, HN1, HN2, HN3), clinical stage (e.g., stage I [HN0/HN1], stage II
26 [HN2/HN3]), type of surgery (marginal [nodulectomy] or wide [pinnectomy]), histologic grade (K-LG or
27 K-HG), histologic margins (complete or incomplete), adherence to underlying cartilage (yes or no) based
28 on histopathology reports, and adjuvant medical treatment (e.g. traditional chemotherapy, tyrosine kinase
29 inhibitors [TKIs], none).

30 In order to assess outcome, the following information was also retrieved: local recurrence (cMCT relapse
31 at or within 2 cm of the surgical scar, confirmed by cytology or histopathology), nodal progression
32 (presence of new metastatic LN/s), distant progression (occurrence of cytologically confirmed metastasis
33 at distant organs), date of death or last follow-up examination, and cause of death.²⁷ Dogs receiving
34 chemotherapy were reassessed at every treatment session, then every 2-3 months for the first year, and
35 every 3-6 months thereafter. Dogs undergoing surgery alone were reassessed every 2-3 months for the

36 first year, and every 3-6 months thereafter. Imaging including abdominal ultrasound, was carried out at
37 the clinicians' discretion, depending on owners' compliance and evidence of progressive disease.

39 Statistical analysis

40 Descriptive statistics were used in the analysis of dogs and tumor characteristics. When appropriate, data
41 sets were tested for normality by use of the D'Agostino and Pearson omnibus normality test. No data had
42 normal distribution and were therefore expressed as median (range).

43 Time to progression (TTP) was calculated from the date of surgery to the first occurrence of at least one
44 of the following events: local recurrence, nodal progression or distant progression.

45 Tumor-specific survival (TSS) was calculated from the date of surgery to the date of death due to tumor-
46 related causes.

47 If tumor progression or death for tumor-related causes did not occur, dogs were censored for the respective
48 statistical analysis.

49 The influence of potential prognostic variables on TTP and TSS was investigated with univariable and
50 multivariable Cox's regression analyses. The following variables were analyzed: breed (predisposition to
51 biologically aggressive MCTs [i.e., Shar pei, American Staffordshire, Weimaraner, Rottweiler, Shih-Tzu]
52 or others),^{13,11,28} sex (male or female), age, body weight, macroscopic tumor longest diameter (> 3 cm or
53 ≤ 3 cm),^{30,31} ulceration (yes or no), substage (a or b), type of surgery (marginal or wide), grading (K-
54 LG or K-HG), margins (complete or incomplete), adherence to cartilage (yes or no), LN status (HN3 or
55 other), clinical stage (I or other), adjuvant medical treatment (yes or no). For age and body weight, the
56 median was used as a cut-off value.

57 Survival plots were generated according to the Kaplan-Meier product limit method. Survival estimates
58 were presented as medians with the corresponding 95% confidence intervals (95% CIs). Survival curves
59 obtained with the Kaplan-Meier method were compared with the log-rank test.

60 The impact of histologic grade (K-LG or K-HG) on the presence of LN metastasis at admission was
61 assessed by binary logistic regression analysis.

62 Statistical analysis was performed using SPSS Statistic v.25 (IBM, Armonk, NY, United States).
63 Significance was set at $p < 0.05$.

65 Cell Line Validation Statement:

66 No cell lines were used in the current study.

68 **Results**

70 Patient data and tumor characteristics:

71 The electronic search between 2014 and 2022 identified 74 dogs potentially suitable for the study.
72 Twenty-nine dogs were excluded as information regarding the SLN/RLN location and/or status was not
73 available, and 6 were excluded as they had multiple head and neck cMCTs at presentation.

74 A total of 39 dogs with cMCTs of the pinnae were ultimately included. There were mixed breeds (n=13;
75 33.4%), Labrador retriever (n=5; 12.8%), golden retriever (n=3; 7.7%), Boxer (n=3; 7.7%), and one
76 (2.5%) each of American Staffordshire, cane Corso, Bernese mountain dog, Maltese, miniature
77 Schnauzer, American bulldog, Beagle, French bouledogue, Brittany, Chihuahua, Shih-Tzu, English
78 springer spaniel, English setter and Vizsla.

79 There were 23 (58.9%) females (of which 18 spayed) and 16 (41.1%) males (of which 8 castrated). The
80 median age was 8 years (range, 1-15 years), and the median weight was 22 kg (range, 7-45.5 kg).

81 Six (15.4%) dogs were symptomatic (n=3 pruritus, n=2 inappetence, n=1 lethargy).

82 Twenty-one (53.8%) tumors were located on the left pinna, while 18 (46.2%) on the right pinna. Median
83 tumor diameter was 2 cm (range, 0.3-5.5 cm); 8 (20.5%) tumors were ulcerated.

84 Information regarding RLN size was available for 15/21 (71.4%) dogs: 11 (73.3%) dogs had subjectively
85 enlarged RLN/s, whereas 4 (26.7%) had normal-sized RLN/s. Among dogs that underwent SLN mapping,
86 information regarding SLN size was available in 13/18 (72.2%) cases: 9 (69.2%) dogs had subjectively
87 normal-sized SLN/s, whereas 4 (30.8%) had enlarged SLN/s.

88 Eighteen (46.2%) dogs underwent SLN mapping by means of CT-lymphangiography: in 9 (50%) cases
89 the superficial cervical LN was the only SLN, and in 8 (44.4%) cases it was at least one of the SLNs
90 (Table 1).

91 Information regarding cytologic evaluation of LN/s was available for 29/39 (74.3%) dogs: 10 (34.5%)
92 LN aspirates were interpreted as normal, 5 (17.2%) as reactive, 4 (13.8%) as possible metastasis, 5
93 (17.2%) as probable metastasis, and 5 (17.2%) as certain metastasis according to Krick's cytological
94 evaluation.³²

95 Thirty-four (87.2%) dogs underwent pinnectomy, while 5 (12.8%) dogs underwent nodulectomy.

96 Based on histopathology, there were 20 (51.3%) K-LG cMCTs and 19 (48.7%) K-HG cMCTs.

97 Information regarding cartilage involvement was available for 29 (74.3%) dogs: in 19 (65.5%) cases there
98 was no cartilage involvement. Surgical margins were complete in 33 (84.6%) cases and incomplete in 6
99 (15.4%); among dogs with incomplete margins, 4 dogs underwent nodulectomy and 2 dogs underwent
00 pinnectomy. Mutational analysis was available for 6 (15.4%) cMCTs: 3 had ITD on exon 11, 1 had ITD
01 on exon 8, and 2 were wild type.

02 Twenty-one (56.4%) dogs underwent regional lymphadenectomy, while 18 (46.2%) underwent SLN/s
03 removal.

04 Overall, 27 SLNs (n=17 superficial cervical; n=6 mandibular; n= 3 parotid; n=1 medial retropharyngeal)
05 and 31 RLNs (n=18 mandibular; n=11 superficial cervical; n=2 medial retropharyngeal) were surgically
06 removed. Based on histopathology, 18 LNs were HN0, 12 HN1, 14 HN2, and 14 HN3. HN3 metastatic
07 LNs included 12 superficial cervical and 2 medial retropharyngeal LNs, while HN2 metastatic LNs

08 included 10 superficial cervical, 2 mandibular and 2 parotid LNs. In all dogs with metastatic MCT the
09 superficial cervical LN was involved alone (n=18) or in addition to other LNs (n=4).

10 Seventeen (43.5%) dogs had stage I disease and 22 (56.5%) dogs had stage II disease. None had distant
11 metastasis.

12 Among dogs with K-LG cMCTs, 13 (65%) had stage I (HN0/HN1) disease and 7 (35%) had stage II (n=6
13 HN2; n=1 HN3) disease. Among dogs with K-HG cMCTs, 4 (21.1%) had stage I disease and 15 (78.9%)
14 had stage II (n=11 HN3; n=4 HN2) disease.

15 Dogs with K-HG cMCTs had a 6.96 fold increased risk of having LN metastasis (HN2/HN3; 95% CI:
16 1.66-29.26; p=0.008) and a 26.13 fold increased risk of having overt (HN3) LN metastasis (95% CI: 2.67-
17 237.55; p=0.004).

18 Overall, 22 (88%) dogs were treated with traditional chemotherapy consisting of vinblastine and
19 prednisolone (n= 20) or lomustine and prednisolone (n=2), and 3 (12%) received TKIs (n=2 masitinib;
20 n=1 toceranib); all dogs with K-HG cMCTs and 6 (30%) dogs with K-LG cMCTs received adjuvant
21 medical treatment. All dogs with K-LG cMCTs treated with adjuvant medical treatment had nodal
22 metastasis (n=5 HN2; n=1 HN3).

23 Outcome and prognostic variables:

24 Fourteen (35.9%) dogs experienced disease progression after a median of 116 days (range, 21-499 days);
25 among them 13 (92.8%) had K-HG cMCTs and 1 (7.2%) had a K-LG cMCT.

26 Eight (20.5%) dogs experienced local recurrence after a median of 147 days (range, 21-320 days), all had
27 K-HG cMCTs; 3 out of these 8 dogs underwent nodulectomy and had their cMCT removed with
28 incomplete margins.

29 Twelve (30.7%) dogs experienced nodal progression after a median of 116 days (range, 21-499 days);
30 among them, 11 (91.7%) had K-HG cMCTs.

31 Six (15.4%) dogs had distant progression after a median of 335 days (range, 90-500 days); all had K-HG
32 cMCTs.

33 At data analysis closure, 23 (59%) dogs were alive with a median follow-up of 569 days (range, 150-1493
34 days), while 16 (41%) dogs had died because of tumor-related (n=13; 81%) or unrelated (n=3; 19%)
35 causes. In the latter, causes of death were appendicular osteosarcoma, congestive heart failure and chronic
36 kidney disease. Among dogs that had died due to tumor-related causes, 12 (92.3%) had K-HG cMCTs
37 and one had a K-LG cMCT.

38 On univariable analysis, substage b (HR: 7.11; p=0.001), marginal surgery (HR: 4.30; p=0.015), K-HG
39 (HR: 25.35; p=0.002), incomplete histological margins (HR: 5.02; p=0.005) and the presence of HN3
40 LNs (HR: 6.6; p<0.001) were significantly associated with higher risk of tumor progression (Table 2).

41 On multivariable analysis, K-HG (HR: 10.38; p=0.043) remained significant (Table 3).

43 On univariable analysis, substage b (HR: 9.00; $p < 0.001$), marginal surgery (HR: 4.56; $p = 0.017$), K-HG
44 (HR: 25.82; $p = 0.002$), incomplete histological margins (HR: 5.53; $p = 0.004$) and the presence of HN3
45 LNs (HR: 12.03; $p < 0.001$) and were significantly associated with higher risk of tumor-related death
46 (Table 2).

47 K-HG was the only variable significantly associated with a higher risk of tumor-related death in
48 multivariable analysis (HR: 14.15; $P = 0.021$; Table 4).

49 Median TTP (mTTP) for dogs with K-HG cMCTs (270 days; 95% CI: 35-505) was significantly shorter
50 than mTTP for dogs with K-LG cMCTs (not reached; 95% CI: 150-2230; $p < 0.01$; Figure 1).

51 Median TSS (mTSS) for dogs with K-HG cMCTs (370 days; 95% CI: 280-460) was significantly shorter
52 than mTSS for dogs with K-LG cMCTs (not reached; 95% CI: 150-1992; $p < 0.01$; Figure 2).

54 Discussion

55 In agreement with previous studies,¹⁴⁻¹⁶ the results of the current work suggest that the superficial cervical
56 LN is most often the SLN in cMCTs of the pinna, as in approximately 95% of cases the superficial cervical
57 LN was at least one of, if not the only SLN.

58 Overall, LN metastasis was detected in 56% dogs at the time of diagnosis, and the superficial cervical LN
59 was always involved in case of metastatic disease, further proving to be the most likely first lymphatic
60 drainage site in dogs with MCT of the pinna. The rate of LN metastasis observed in our study is higher
61 when compared to a previous study, in which nodal metastasis was not identified in any of the included
62 dogs with cMCTs of the pinna.¹² It is important to note that in Schwab's study only 2/28 (7%) dogs
63 underwent cytologic evaluation of the mandibular LN and that no lymphadenectomy was performed.¹²
64 Additionally, the superficial cervical LN was never investigated, possibly missing metastatic foci. Our
65 results confirm in a larger population the findings of De Bonis and colleagues, where one out of two dogs
66 with cMCTs of the pinna had SLN metastasis (superficial cervical LN; HN3).¹⁵

67 Interestingly, approximately 50% of cMCTs of the pinna in this study were histologically K-HG. These
68 results suggest that cMCTs located on the pinnae may be associated with higher histologic grade as
69 compared to cMCTs of other locations. In Schwab's study, 28.6% of MCTs of the pinna were
70 histologically classified as Patnaik P-GIII, while 57.1% and 14.3% tumors were classified as P-GII and
71 P-GI, respectively.¹² Although it is difficult to compare our results with the aforementioned study due to
72 the different grading systems, it is plausible that a portion of P-GII tumors were K-HG cMCTs.^{12, 35}

73 This discrepancy may be due to the involvement of referral oncology centers in the current study, which
74 deal more frequently with aggressive tumors, leading to a possible selection bias.

75 In agreement with a previous study,³⁰ we found a significant correlation between the histologic grade of
76 the primary tumor and LN status, since dogs with K-HG cMCTs had a higher risk of developing nodal
77 metastasis when compared to dogs with K-LG tumors.

78 Furthermore, the current study confirmed the independent prognostic value of histologic grading: the
79 presence of K-HG cMCTs was significantly associated with a higher risk of both tumor progression and
80 tumor-related death, and outclassed the impact of nodal metastasis in multivariable analysis.

81 The prognosis for dogs with K-HG cMCTs undergoing multimodal treatment, consisting of surgical
82 excision of the primary tumor, lymphadenectomy and adjuvant medical treatment, was not unfavorable,
83 even in the presence of LN metastasis (15/19 cases; 78.9%), with a mTSS of 370 days. These findings
84 support recent studies in which outcome is improved if a multimodal treatment is pursued.^{31, 37} In one
85 study, dogs with K-HG cMCTs and LN metastasis (stage II) that underwent surgical excision of the
86 primary tumor, lymphadenectomy, with or without LN bed irradiation, had a median progression free
87 survival and overall survival of 125 and 330 days, respectively.³¹ In a more recent study, dogs with K-
88 HG cMCTs and HN3 LN that underwent lymphadenectomy as part of their primary surgery and received
89 adjuvant medical treatment had mTTP and survival time of 277 and 371 days, respectively.³⁷

90 Here, mTTP and mTSS for dogs with stage II K-LG cMCTs were not reached, as few events occurred;
91 most (6/7; 85.7%) of them had HN2 LNs. Among those, only one dog with early metastasis did not receive
92 adjuvant medical treatment. It has been previously suggested that dogs with surgically removed K-LG
93 cMCTs that undergo concurrent excision of an HN2 LN do not necessarily require adjuvant
94 chemotherapy.³⁸ Thus, it is possible that even without adjuvant medical treatment the prognosis for these
95 dogs would have still been favorable.

96 Recent studies showed that the removal of an early and/or overtly metastatic LN is associated with a better
97 outcome in both LG and HG cMCTs.^{27, 31, 37} Considering the above, clinicians should be aware that in
98 most cases of pinnal cMCT the superficial cervical LN is the SLN, and in the authors' opinion this should
99 always be investigated even in the absence of more sophisticated imaging techniques.

00
01 The current study has several limitations mainly due to its retrospective design. First, despite performing
02 a multi-institutional study, inclusion criteria were strict; this, in addition to the low frequency of cMCT
03 on the pinna, resulted in a relatively small sample size.

04 Second, not all dogs underwent SLN mapping, precluding a more detailed analysis of SLNs. Third, LNs
05 were histologically evaluated by multiple pathologists and slides were not reviewed, potentially affecting
06 results. Finally, follow-up was not standardized, potentially biasing results.

07
08 In conclusion, the present study showed that cMCTs of the pinna are often K-HG and are also associated
09 with a higher frequency of LN metastasis. Moreover, the superficial cervical LN is most often the SLN
10 in dogs with pinnal cMCTs. Although the pinnal anatomical location has been previously associated with
11 more aggressive biologic behavior, a multimodal treatment may lead to favorable long-term outcome.

12
13
14 **References**

- 15 1. Blackwood L, Murphy S, Buracco P, et al. European consensus document on mast cell tumours
16 in dogs and cats. *Vet Comp Oncol* 2012;10(3):e1-e29.
- 17 2. Pizzoni S, Sabattini, Stefanello S, et al. Features and prognostic impact of distant metastases in
18 45 dogs with de novo stage IV cutaneous mast cell tumours. A prospective study. *Vet Comp*
19 *Oncol* 2018;16(1):28-36.
- 20 3. Gieger TL, Théon AP, Werner JA, McEntee MC, Rassnick KM, DeCock HEV. Biologic
21 behaviour and prognostic factors for mast cell tumours of the canine muzzle: 24 cases (1990–
22 2001). *J Vet Intern Med* 2003;17(5):687–92.
- 23 4. Bellamy E, Berlato D. Canine cutaneous and subcutaneous mast cell tumors: a narrative review.
24 *J Small Anim Pract* 2021;63(7):497-511.
- 25 5. Dobson J, Cohen S, Gould S. Treatment of canine mast cell tumors with prednisolone and
26 radiotherapy. *Vet Comp Oncol* 2004;2(3):132-141.
- 27 6. Sfiligoli, G, Rassnick, KM, Scralett, JM, Northrup NC, Gieger TL. Outcome of dogs with mast
28 cell tumours in the inguinal or perineal region versus other cutaneous locations: 124 cases
29 (1990-2001). *J Am Vet Med Assoc* 2005;226(8):1368-1374.
- 30 7. Hillman AL, Garrett DL, Lorimier DPL, Charney SC, Borst LB, Fan TM. Biological behaviour
31 of oral and perioral mast cell tumours in dogs: 44 cases (1996-2006). *J Am Vet Med Assoc* 2010;
32 237(8):936-942.
- 33 8. Elliott WJ, Cripps P, Blackwood L, Berlato D, Murphy S, Grant IA. canine oral mucosal mast
34 cell tumours. *Vet Comp Oncol* 2016;14(1):101-111.
- 35 9. Misdorp W. Mast cells and canine mast cell tumours. A review. *Vet Q* 2012;26(4):156-169.
- 36 10. Hahn KA, King GK, Carreras JK. Efficacy of radiation therapy for incompletely resected grade-
37 III mast cell tumours in dogs: 31 cases (1987-1998). *J Am Vet Med Assoc* 2004;224(1):79-82.
- 38 11. Śmiech A, Ślaska B, Łopuszyński W, Jasik A, Bochynska D, Dabrowski R. Epidemiological
39 assessment of the risk of canine mast cell tumours based on the Kiupel two-grade malignancy
40 classification. *Acta Vet Scand* 2018;60(1):70.
- 41 12. Schwab TM, Popovitch C, DeBiasio J, Goldschmidt M. Clinical outcome for MCTs of canine
42 pinnae treated with surgical excision (2004-2008). *J Am Anim Hosp Assoc* 2014;50(3):187-191.
- 43 13. Mochizuki H, Reif-Mostinger M, Bettini C, Moroff S, Breen M. Association of breed and
44 histopathological grade in canine mast cell tumours. *Vet Comp Oncol* 2017;15(3):829-839.
- 45 14. Worley DR. Incorporation of sentinel lymph node mapping in dogs with mast cell tumours: 20
46 consecutive procedures. *Vet Comp Oncol* 2014;12(3):215-226.
- 47

- 48 15. De Bonis A, Collivignarelli F, Paolini I, et al. Sentinel lymph node mapping with indirect
49 lymphangiography for canine mast cell tumour. *Vet Sci* 2022; 9(9):484.
- 50 16. Grimes JA, Secrest SA, Wallace ML, Laver T, Schmiedt CW. Use of indirect computed
51 tomography lymphangiography to determine metastatic status of sentinel lymph nodes in dogs
52 with pre-operative diagnosis of melanoma or mast cell tumours. *Vet Comp Oncol*
53 2020;18(4):818-824.
- 54 17. Lapsley J, Hayes HG, Janvier V, et al. Influence of locoregional lymph node aspiration cytology
55 vs sentinel lymph node mapping and biopsy on disease stage assignment in dogs with
56 integumentary mast cell tumors. *Vet Surg* 2021;50(1):133-141.
- 57 18. Owen LN. Skin mastocytoma. In:TNM classification of tumors in domestic animals. 1st ed.
58 Geneva: World 474 Health Organization; 1980.
- 59 19. Weishaar KM, Thamm DH, Worley DR, Kamstock DA. Correlation of nodal mast cells with
60 clinical outcome in dogs with mast cell tumor and a proposed classification system for the
61 evaluation of node metastasis. *J Comp Pathol* 2014;151(4):329-338.
- 62 20. Young JT. Green coloration of superficial cervical lymph nodes in dogs tattooed in the ear.
63 *Zentralbl Veterinarmed A* 1986;33(10):788-790.
- 64 21. Suami H, Yamashita S, Miranda-Soto MA, Chang DW. Lymphatic territories (lymphosomes) in
65 a canine: an animal model for investigation of postoperative lymphatic alterations. *PLoS One*
66 2013;8(7):e69222.
- 67 22. Baum H. The Lymphatic System of the Dog. Saskatoon, SK, Canada, University of
68 Saskatchewan; 2021.
- 69 23. Ferrari R, Chiti LE, Manfredi M, et al. Biopsy of sentinel lymph nodes after injection of
70 methylene blue and lymphoscintigraphic guidance in 30 dogs with mast cell tumors. *Vet Surg*
71 2020;49(6):1099-1108.
- 72 24. Rossi F, Körner M, Suárez J, et al. Computed tomographic-lymphography as a complementary
73 technique for lymph node staging in dogs with malignant tumors of various sites. *Vet Radiol*
74 *Ultrasound* 2018;59(2):155-162.
- 75 25. Randall KE, Jones DM, Kraft LS, Worley RD. The development of an indirect computed
76 tomography lymphography protocol for sentinel lymph node detection in head and neck cancer
77 and comparison to other sentinel lymph node mapping techniques. *Vet Comp Oncol*
78 2020;18(4).634-644.
- 79 26. Kiupel M, Webster JD, Bailey KL, et al. Proposal of a 2-tier histologic grading 448 system for
80 canine cutaneous mast cell tumors to more accurately predict biological behaviour. *Vet Pathol*
81 2011;48(1):147–155.

- 82 27. Marconato L, Polton G, Stefanello D, et al. Therapeutic impact of regional lymphadenectomy in
83 canine stage II cutaneous mast cell tumors. *Vet Comp Oncol* 2018;16(4):680-589.
- 84 28. Krick LE, Billings PA, Shofer SF, Watanabe S, Sorenmo UK. Cytological lymph node
85 evaluation in dogs with mast cell tumors: association with grade and survival. *Vet Comp*
86 *Oncol*;7(2):130-138.
- 87 29. Śmiech A, Łopuszyński W, Ślaska, Bulak K, Jasik A. Occurrence and Distribution of Canine
88 Cutaneous Mast Cell Tumour Characteristics Among Predisposed Breeds. *J Vet Res*
89 2019;63(1):141-148.
- 90 30. Stefanello D, Buracco P, Sabbatini S, et al. Comparison of 2- and 3-category histologic grading
91 systems for predicting the presence of metastasis at the time of initial evaluation in dogs with
92 cutaneous mast cell tumors: 386 cases (2009-2014). *J Am Vet Med Assoc* 2015; 246(7):765-769.
- 93 31. Mendez SE, Drobatz KJ, Duda LE, White P, Kubicek L, Sorenmo KU. Treating the locoregional
94 lymph node with radiation and/or surgery significantly improves outcome in dogs with high-
95 grade mast cell tumors. *Vet Comp Oncol* 2020;18(2):239-246.
- 96 32. Krick LE, Billings PA, Shofer SF, Watanabe S, Sorenmo KU. Cytological lymph node
97 evaluation in dogs with mast cell tumors: association with grade and survival. *Vet Comp*
98 *Onol*;7(2):130-138.
- 99 33. Ferrari R, Boracchi P, Chiti LE, et al. Assessing the risk of nodal metastases in canine
00 integumentary mast cell tumorous: is sentinel lymph node biopsy always necessary? *Animals*
01 (*Basel*) 2021;11(8):2373.
- 02 34. Mullins MN, Dernell WS, Withrow SJ, Ehrhart EJ, Thamm DH, Lana SE. Evaluation of
03 prognostic factors associated with outcome in dogs with multiple cutaneous mast cell tumors
04 treated with surgery with and without adjuvant treatment: 54 cases (1998-2004). *J Am Vet Med*
05 *Assoc* 2006;228(1):91-95.
- 06 35. Thamm DH, Mauldin EA, Vail DM. Prednisone and vinblastine chemotherapy for canine mast
07 cell tumor: 41 cases (1992-1997). *J Vet Intern Med* 1999;13(5):491-497.
- 08 36. Sabattini S, Scarpa F, Berlato D, Bettini G. Histologic grading of canine mast cell tumor: is 2
09 better than 3? *Vet Pathol* 2015;52(1):70-73.
- 10 37. Chalfon C, Sabbatini S, Finotello R, et al. Lymphadenectomy improves outcome in dogs with
11 resected Kiupel high-grade cutaneous mast cell tumours and overtly metastatic regional lymph
12 nodes. *J Small Anim Pract* 2022;63(9):661-669.
- 13 38. Marconato L, Stefanello D, Kiupel M, et al. Adjuvant medical therapy provides no therapeutic
14 benefit in the treatment of dogs with low-grade mast cell tumors and early nodal metastasis
15 undergoing surgery. *Vet Comp Oncol* 2020;18(3):409-415.

16
17

Table 1. SLN/s location among 18 dogs with cMCTs of the pinna that underwent SLN mapping.

cMCT [†] location	Identified SLN [‡]
Right pinna	Right superficial cervical (n=5)
Left pinna	Left superficial cervical (n=5)
Right pinna	Right superficial cervical and right mandibular (n=2)
Left pinna	Left superficial cervical and left mandibular (n=1)
Left pinna	Left superficial cervical and left parotid (n=1)
Right pinna	Right superficial cervical and right parotid (n=1)
Left pinna	Left superficial cervical, left parotid and left mandibular (n=1)
Left pinna	Left superficial cervical and left medial retropharyngeal (n=1)
Right pinna	Right mandibular (n=1)

18
19
20
21
22
23

[†]cutaneous mast cell tumor; [‡] sentinel lymph node.

Table 2. Univariable Cox regression analysis of variables potentially associated with increased risk of tumor progression and tumor-related death in 39 dogs with cMCTs of the pinnae.

Variable	Tumor progression		Tumor-related death	
	Hazard Ratio (95% CI [†])	<i>P</i>	Hazard Ratio (95% CI)	<i>P</i>
Breed predisposed to biologically aggressive cMCT [‡]	>0.99 (0.27-3.62)	0.994	1.16 (0.31-4.29)	0.828
Age ≥ 7 years	2.10 (0.69-6.46)	0.194	1.81 (0.57-5.73)	0.313
Female sex	1.55 (0.52-4.61)	0.432	1.30 (0.42-4.03)	0.652
Weight ≥ 22 kg	0.59 (0.19-1.81)	0.359	0.73 (0.23-2.31)	0.595
Tumor diameter > 3 cm	1.47 (0.49-4.38)	0.491	1.21 (0.38-3.81)	0.749
Ulceration	2.07 (0.64-6.75)	0.227	2.17 (0.65-7.23)	0.206
Substage b	7.11 (2.29-22.07)	0.001*	9.00 (2.75-29.47)	<0.001*
Marginal surgery	4.39 (1.33-14.46)	0.015*	4.56 (1.31-15.86)	0.017*
K-HG [¶]	24.35 (3.15-188.37)	0.002*	25.82 (3.27-204.06)	0.002*
Incomplete histological margins	5.02 (1.64-15.34)	0.005*	5.53 (1.73-17.71)	0.004*
Presence of adherence to cartilage	1.10 (0.27-4.40)	0.899	1.51 (0.36-6.38)	0.577
HN3 LN [§]	6.60 (2.18-20.04)	0.001*	12.03 (3.19-45.34)	<0.001*

Clinical stage>I	66.89 (0.75-5933.68)	0.066	71.78 (0.66-7773.95)	0.074
Adjuvant oncological medical treatment	0.02 (0.00-1.76)	0.086	0.02 (0-2.25)	0.104

†confidence interval; ‡ cutaneous mast cell tumor; ¶ Kiupel high grade; § lymph node; *significant.

Table 3. Multivariable Cox regression analysis for risk of tumor progression in 39 dogs with cMCTs of the pinna. Variables with $p \leq 0.05$ at univariable analysis were included in the model.

Variable	Tumor progression	
	Hazard Ratio (95% CI†)	P
Substage b	1.50 (0.40-5.61)	0.545
Marginal surgery	2.91 (0.48-17.61)	0.246
K-HG‡	10.38 (1.07-100.50)	0.043*
Incomplete histological margins	1.83 (0.39-8.61)	0.445
HN3 LN§	1.50 (0.40-5.61)	0.545

†confidence interval; ‡ Kiupel high grade; § lymph node; *significant.

Table 4. multivariable Cox regression analysis for the risk of tumor-related death in 39 dogs with cMCTs of the pinna. Variables with $p \leq 0.05$ at univariable analysis at univariable analysis were included in the model.

Variable	Tumor-related death	
	Hazard Ratio (95% CI†)	P
Substage b	2.91 (0.52-16.22)	0.224
Marginal surgery	2.53 (0.44-14.61)	0.299
K-HG‡	14.15 (1.50-133.85)	0.021*
Incomplete histological margins	2.06 (0.50-8.48)	0.318
HN3 LN§	3.78 (0.73-19.46)	0.112

†confidence interval; ‡ Kiupel high grade; § lymph node; *significant.

Figure 1. Time to progression for dogs with Kiupel high-grade vs Kiupel low-grade cutaneous mast cell tumors of the pinna. Median time to progression for dogs with Kiupel high-grade tumors was significantly shorter than median time to progression for dogs with Kiupel low-grade tumors (270 days vs not reached, respectively; $p < 0.01$).

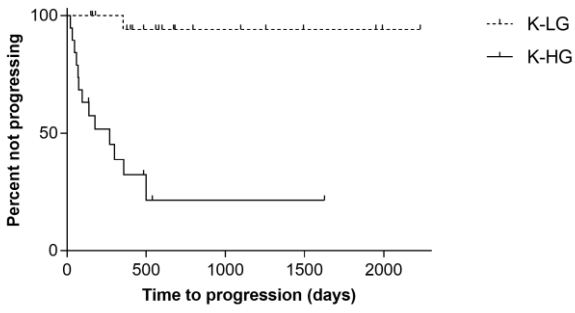


Figure 2. Tumor-specific survival for dogs with Kiupel high-grade vs Kiupel low-grade cutaneous mast cell tumors of the pinna. Median tumor-specific survival for dogs with Kiupel high-grade tumors was significantly shorter than median tumor-specific survival for dogs with Kiupel low-grade tumors (370 days vs not reached, respectively; $p < 0.01$).

