

# Takayasu's arteritis and an elevated antistreptolysin O titre – a potentially expensive diagnostic conundrum

Oliver Lloyd<sup>1</sup>, Simon Lammy<sup>2</sup>, Rebecca Edwards<sup>3</sup> and Robert Laing<sup>4</sup>

<sup>1</sup>Department of Cardiology, Aberdeen Royal Infirmary, Aberdeen AB25 2ZN, UK

<sup>2</sup>Department of Surgery, Aberdeen Royal Infirmary, Aberdeen AB25 2ZN, UK

<sup>3</sup>Department of Microbiology, Aberdeen Royal Infirmary, Aberdeen AB25 2ZN, UK

<sup>4</sup>Infection Unit, Aberdeen Royal Infirmary, Aberdeen AB25 2ZN, UK

**Corresponding author:** Oliver Lloyd. Email: o.lloyd@doctors.org.uk

## Lesson

Takayasu's arteritis is a chronic large vessel vasculitis which may be associated with a false positive antistreptolysin O titre.

## Keywords

Antistreptolysin O Titre, Takayasu's arteritis

## Case report

A 19-year-old Caucasian woman was referred with a four-month history of exertional chest tightness radiating to the left arm. Occasionally this had been associated with palpitations and dizziness. She took no medications, was a non-smoker and consumed moderate alcohol. There was no history of illicit drug use. Her grandfather had suffered from ischaemic heart disease.

Physical examination yielded blood pressure 114/60 mmHg, a regular pulse, no pulse deficits, normal heart sounds and murmurs consistent with mixed aortic valve disease. The jugular venous pressure was normal with clear lung fields. There was no evidence of arthritis or rashes.

A resting 12-lead electrocardiogram showed sinus rhythm meeting voltage criteria for left ventricular hypertrophy. A subsequent exercise tolerance test was electrically and symptomatically positive with significant widespread ST-segment depression.

Trans-thoracic echocardiography revealed a dilated ascending aorta with severe aortic regurgitation. Magnetic resonance angiography confirmed a dilated aortic root with significant mural thickening from the aortic root to the arch.

Laboratory investigations revealed a markedly elevated erythrocyte sedimentation rate (ESR) 92 mm (at only 25 min), C-reactive protein (CRP) 48 mg/L, WCC  $11.0 \times 10^9/L$ , IgG 24.27 g/L and antistreptolysin O titre (ASOT) 3840 U/mL. Urea and

electrolytes, liver function tests, anti-nuclear antibody, anti-neutrophil cytoplasmic antibody, C3 and C4 were normal. HIV, syphilis and toxoplasma gondii antibodies were negative. Serology was consistent with previous Epstein–Barr virus and cytomegalovirus infection.

<sup>18</sup>F-FDG PET/CT revealed increased metabolic activity in the wall of the aorta extending from root to arch, showing an active large vessel arteritis consistent with Takayasu's arteritis (TA) (Figure 1).

The patient was treated with oral Prednisolone and Mycophenolate Mofetil. Concurrent intravenous Benzylpenicillin was given to cover the possibility of rheumatic fever. A repeat ASOT was persistently elevated but additional serum testing for anti-DNAse B and *Streptococcal emm* gene was negative, whereupon Benzylpenicillin was stopped.

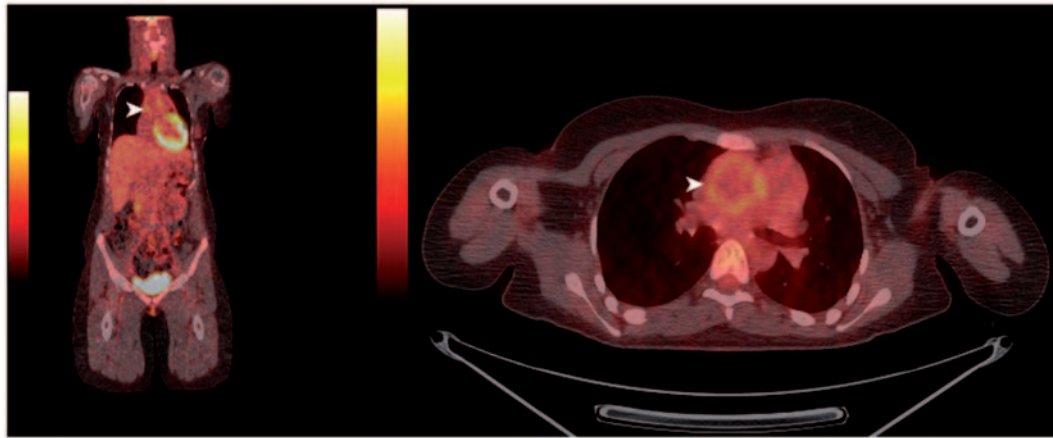
After two weeks of immunosuppressant therapy, there was a significant fall in inflammatory markers, with ESR 10 mm/h and CRP <4 mg/L. Subsequent coronary angiography and aortography revealed critical left main stem ostial stenosis and severe aortic regurgitation.

Following referral to a quaternary cardiothoracic centre, the patient underwent aortic root and mechanical aortic valve replacement, left main stem arterioplasty with re-implantation and precautionary coronary artery bypass grafting. Histopathology of the aortic root supported the clinical and radiological diagnosis of TA.

## Discussion

TA is a chronic large vessel vasculitis affecting the aorta and its main branches.<sup>1</sup> It is a rare disease in the UK, with a reported mean prevalence of 4.7 per million in primary care and 7.1 per million in a secondary care setting.<sup>2</sup> A study from Italy suggests coronary artery involvement is an uncommon finding in the West.<sup>3</sup>

**Figure 1.** Coronal and axial images of fused PET/CT. Arrows indicate abnormal 18F-FDG uptake in the wall of the ascending aorta.



**Table 1.** Aetiology of aortitis.<sup>3</sup>

Inflammatory
Large vessel vasculitis
Takayasu's arteritis
Giant cell arteritis
Rheumatoid arthritis
Systemic lupus erythematosus
HLA-B27 associated spondyloarthropathies
ANCA associated vasculitides
Granulomatous polyangiitis
Microscopic polyangiitis
Polyarteritis nodosum
Behçet disease
Cogan syndrome
Relapsing polychondritis
Sarcoidosis
Isolated idiopathic (thoracic) aortitis
Chronic periaortitis
Rheumatic fever

(continued)

**Table 1.** Continued.

Infectious
Bacterial
<i>Salmonella</i> spp.
<i>Staphylococcus</i> spp.
<i>Streptococcus pneumoniae</i>
Other
Leitic (syphilis)
Mycobacterial
Other

There are many causes of aortitis (Table 1) and a significantly elevated ASOT in our patient raised the possibility of rheumatic fever, creating diagnostic uncertainty.<sup>4</sup> Before continuing with immunosuppressant therapy alone for suspected active large vessel vasculitis, it was therefore important to exclude group A *Streptococcal* infection.

Serum antibody testing against more than one group A *Streptococcal* antigen increases the diagnostic sensitivity for *Streptococcal* infection.<sup>5</sup> DNA amplification of the *Streptococcal emm* gene can also provide evidence of *Streptococcal* infection.<sup>6</sup> The combined negative results for anti-DNase B antibody and serum *emm* gene in our patient confirmed the

elevated ASOT was a false positive result due to cross reactivity. Current in-house testing for ASOT costs approximately £8 and testing for anti-DNAse B and *emm* gene, £45 and £136, respectively at the UK national reference laboratory. By contrast, a 10 day course of intravenous benzylpenicillin 1.2 g qds costs £75 and prophylactic oral penicillin V 250 mg bd until the age of 40 costs £400.<sup>7</sup> Although additional testing for *Streptococcal* infection carries a cost, negative results remain cheaper than empiric long-term treatment.

The association between an elevated ASOT and TA has been described previously, with 19% of patients returning an ASOT twice the upper limit of normal in one study.<sup>8</sup> However, searching PubMed with simple terms (antistreptolysin O antibody and Takayasu) does not yield relevant results regarding this association. We feel it is important to reiterate the potential for false positive ASOT in the context of TA, as misinterpretation could lead to incorrect long-term treatment.

At six months following operation, the patient remained in remission from vasculitis, with normal inflammatory markers and only residual uptake on PET/CT related to postoperative changes.

#### Declarations

**Competing interests:** None declared

**Funding:** None declared

**Ethical approval:** Written informed consent for publication was obtained from the patient.

**Guarantor:** OL

**Contributorship:** OL is lead author. SL, RE and RL all contributed to writing of the case report and approved final version.

**Acknowledgements:** We wish to thank NHS Grampian, the Infection Unit and the Department of Cardiology at Aberdeen Royal Infirmary.

**Provenance:** Not commissioned; peer-reviewed by Juan Pérez-Calvo and Sam Creavin.

#### References

1. Maffei S, Di Renzo M, Bova G, Auteri A and Pasqui AL. Takayasu's arteritis: A review of the literature. *Intern Emerg Med* 2006; 1: 105–112.
2. Watts R, Al-Taiar A, Mooney J, Scott D and Macgregor A. The epidemiology of Takayasu arteritis in the UK. *Rheumatology* 2009; 48: 1008–1011.
3. Vanoli M, Daina E, Salvarani C, et al. Takayasu's arteritis: A study of 104 Italian patients. *Arthritis Rheum* 2005; 53: 100–107.
4. Gornik HL and Creager MA. Aortitis. *Circulation* 2008; 117: 3039–3051.
5. Johnson DR, Kurlan R, Leckman J and Kaplan EL. The human immune response to streptococcal extracellular antigens: Clinical, diagnostic, and potential pathogenetic implications. *Clin Infect Dis* 2010; 50: 481–490.
6. Rogers S, Commons R, Danchin MH, et al. Strain prevalence, rather than innate virulence potential, is the major factor responsible for an increase in serious group A streptococcus infections. *J Infect Dis* 2007; 195: 1625–1633.
7. Joint Formulary Committee. *British National Formulary* (online). London: BMJ Group and Pharmaceutical Press, <http://www.medicinescomplete.com> (accessed on 27 February 2014).
8. Nakao K, Ikeda M, Kimata S, et al. Takayasu's arteritis: Clinical report of eighty four cases and immunological studies of seven cases. *Circulation* 1967; 35: 1141–1155.