

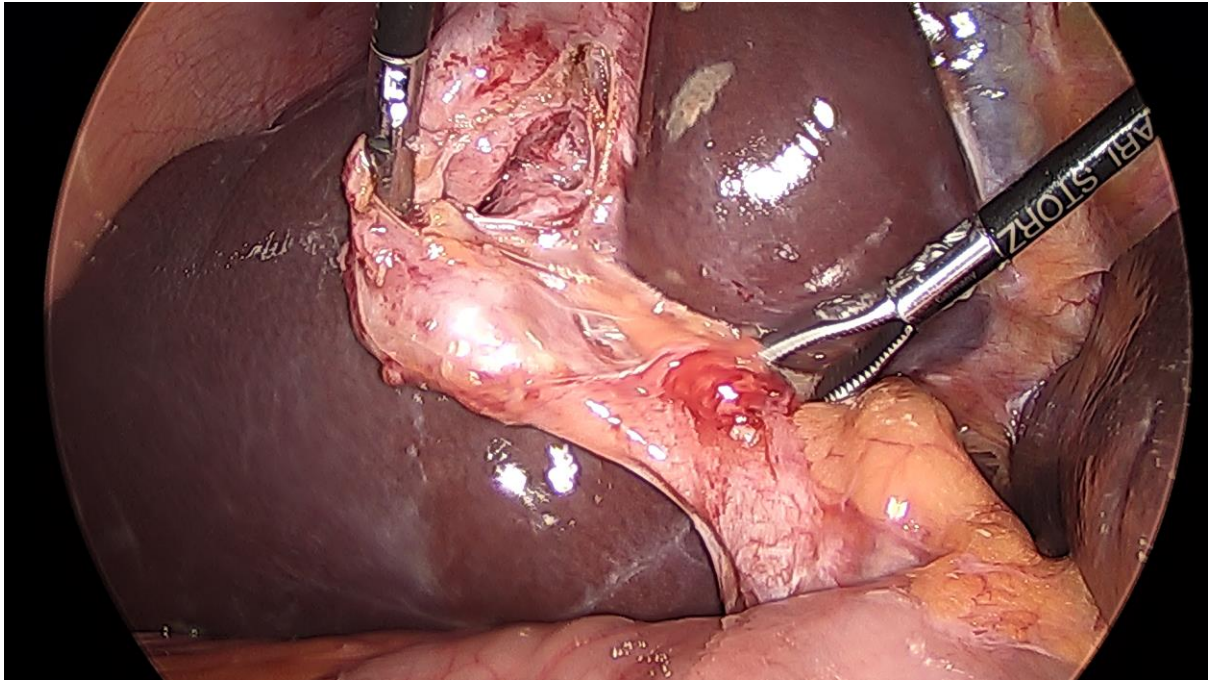Figure 1: Early identification of cystic lymph node.

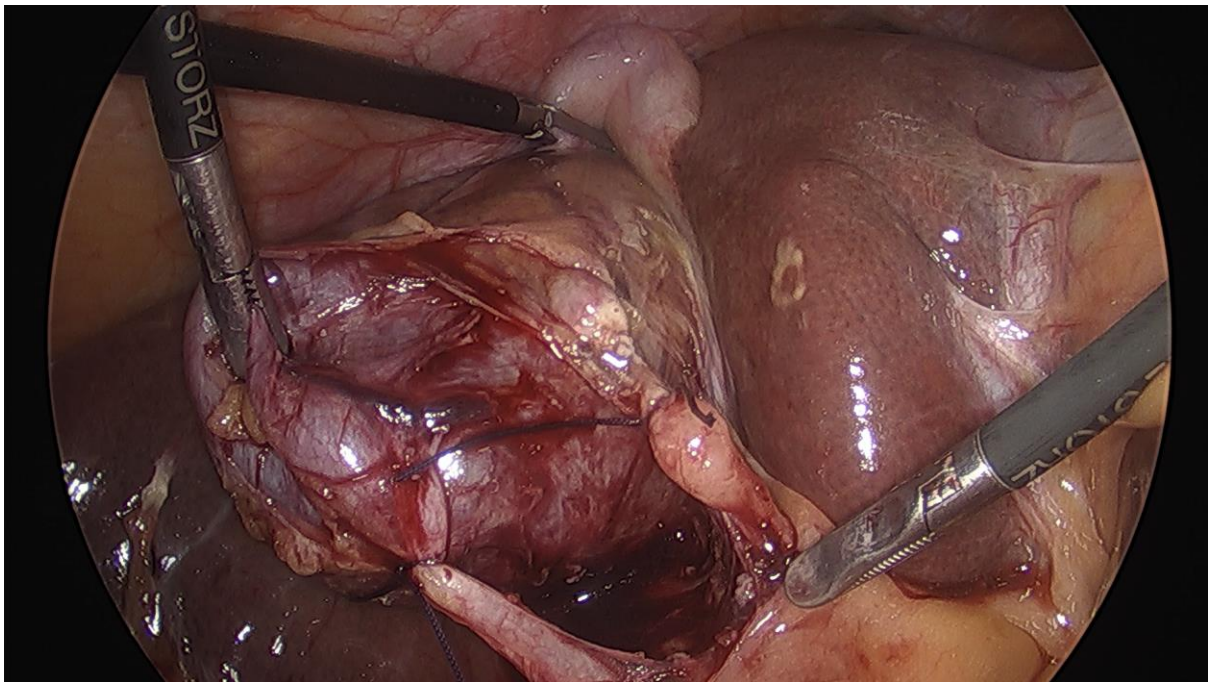


Figure 2: Demonstration of critical view of safety and shows cystic artery ligation between 2 lymph nodes.