



## Variations and anomalies in the vertebral column of the bottlenose dolphin (*Tursiops truncatus*) from southern Brazil

Ana Paula Borges Costa<sup>†,‡,\*</sup>, Carolina Loch<sup>†,§</sup> and Paulo César Simões-Lopes<sup>†</sup>

<sup>†</sup>Laboratório de Mamíferos Aquáticos (LAMAQ), Departamento de Ecologia e Zoologia, Universidade Federal de Santa Catarina. P.O. Box 5102, 88040-970 Florianópolis, SC, Brazil

<sup>‡</sup>Department of Biology, University of Louisiana at Lafayette. 410 E. St. Mary Blvd., 70503 Lafayette, LA, USA

<sup>§</sup>Geology Department, University of Otago. P.O. Box 56, 9054 Dunedin, New Zealand

\*Corresponding author, e-mail: [abc2978@louisiana.edu](mailto:abc2978@louisiana.edu)

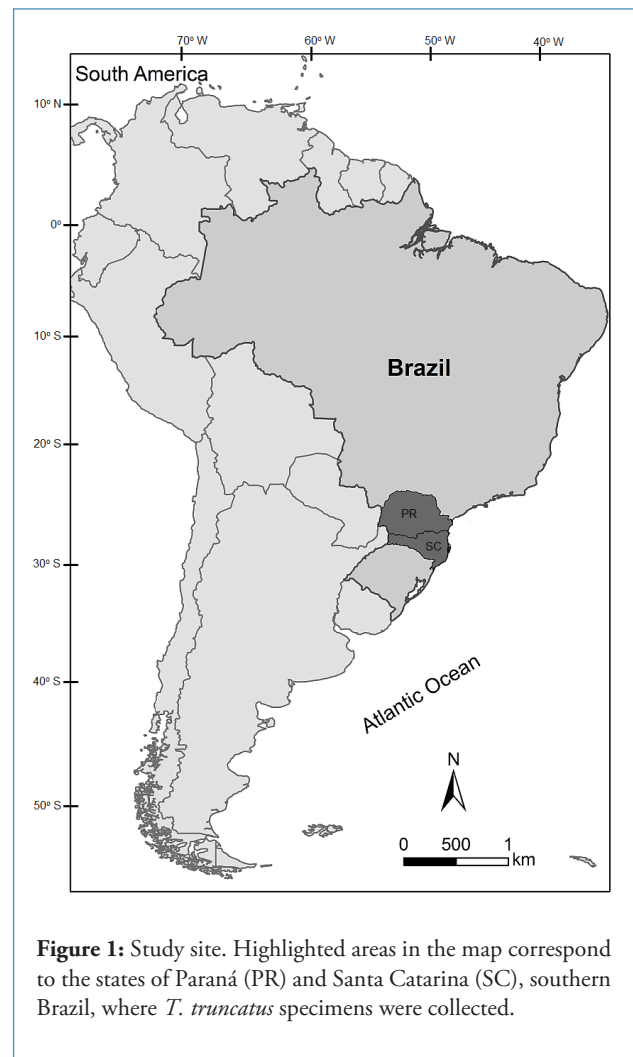
### ARTICLE INFO

Manuscript type	Note
<b>Article history</b>	
Received	22 November 2011
Received in revised form	07 February 2014
Accepted	07 February 2014
Available online	29 December 2016
<b>Responsible Editor:</b> Carlos Olavarria	
<b>Citation:</b> Costa, A.P.B., Loch, C. and Simões-Lopes, P.C. (2016) Variations and anomalies in the vertebral column of the bottlenose dolphin ( <i>Tursiops truncatus</i> ) from southern Brazil. <i>Latin American Journal of Aquatic Mammals</i> 11(1-2): 212-219. <a href="http://dx.doi.org/10.5597/lajam00230">http://dx.doi.org/10.5597/lajam00230</a>	

Cases of bone and joint abnormalities in cetaceans have been reported in the literature; however, most of them have been related to traumatic events, pathology and degenerative joint lesions, and little is known about individual morphological variation or anomalies (Alexander *et al.*, 1989; Long *et al.*, 1997; Furtado and Simões-Lopes, 1999; Kompanje, 1999; Berghan and Visser, 2000; Watson *et al.*, 2004; Sweeny *et al.*, 2005; Galatius *et al.*, 2009).

Variation in the biological sense comprises differences of any kind between individuals, implying a deviation from a mean or a 'norm'. When the difference is slight and common among individuals, it can be considered a 'normal variation'. On the other hand, when the deviations are more conspicuous and uncommon, they are considered anomalies (Miles and Grigson, 1990). Morphological variation can be caused by abnormal deviations during the ontogenetic development of the individual (Winter<sup>1</sup>, as cited by Berghan and Visser, 2000). The lack of knowledge about these anomalies can lead to taxonomic errors; however, their study can increase the understanding about the origin and evolution of diseases and abnormal conditions (Ferigolo, 1987).

Previous studies described these variations in cetaceans<sup>2</sup> (Furtado and Simões-Lopes, 1999; Berghan and Visser,



**Figure 1:** Study site. Highlighted areas in the map correspond to the states of Paraná (PR) and Santa Catarina (SC), southern Brazil, where *T. truncatus* specimens were collected.

<sup>1</sup> Winter, R.B. (1995) Congenital spinal deformity. Pages 257-294 in Winter, R.B., Lonstein, J.E. and Bradford, D.S. (Eds) *Moe's textbook of scoliosis and other spinal deformities*. W.B. Saunders Co., Philadelphia, PA, USA.

<sup>2</sup> Crovetto, A. (1982) À propos d'une malformation laterale de la colonne vertébrale d'une baleine bleue, *Balaenoptera musculus* L. (Cetacea, Balaenopteridae) et de sa signification fonctionnelle. Pages 89-98 in Proceedings, 107 Congrès National Société Savantes, Sciences, Fasc. II, 5-10 April 1982, Brest, France.

**Table 1.** Specimens of *Tursiops truncatus* analyzed in this study. Ecotype classification according to Costa *et al.* (2016). SC = state of Santa Catarina.

UFSC	Collection date	Locality	Ecotype
1011	20 November 1985	Morro das Pedras, Florianópolis, SC	offshore
1072	9 October 1988	Costeira do Pirajubaé, Florianópolis, SC	coastal <sup>a</sup>
1099	20 February 1991	Praia dos Ingleses, Florianópolis, SC	offshore
1103	18 June 1991	Praia do Meio, Navegantes, SC	coastal <sup>a</sup>
1105	1 October 1991	Praia da Joaquina, Florianópolis, SC	unknown <sup>b</sup>
1106	November 1991	Praia da Joaquina, Florianópolis, SC	offshore <sup>a</sup>
1123	24 September 1993	São José, SC	coastal <sup>a</sup>
1126	8 December 1993	Saco dos Limões, Florianópolis, SC	coastal <sup>a</sup>
1209	24 December 1994	Praia do Sol, Imbituba, SC	offshore
1210	24 December 1994	Praia do Sol, Imbituba, SC	fetus of UFSC 1209
1225	9 September 1996	Laguna, SC	coastal <sup>a</sup>
1230	24 March 1997	Praia da Galheta, Florianópolis, SC	offshore <sup>a</sup>
1243		State of Paraná	unknown <sup>b</sup>
1249	16 July 1998	Laguna, SC	coastal
1252	22 August 1998	Itaguaçu, São Francisco do Sul, SC	offshore
1261	8 June 1999	Praia do Santinho, Florianópolis, SC	offshore
1281	20 October 2000	Baía Sul, Florianópolis, SC	coastal
1285	15 November 2001	Laguna, SC	coastal
1287	2 March 2001	Praia da Joaquina, Florianópolis, SC	offshore
1295	21 March 2002	Laguna, SC	coastal
1299	31 March 2001	Praia Grande, São Francisco do Sul, SC	offshore
1317	9 October 2003	Praia dos Ingleses, Florianópolis, SC	offshore
1322	24 October 2003	Coral Island, SC	offshore
1334	27 July 2006	Ribeirão da Ilha, Florianópolis, SC	coastal <sup>a</sup>
1349	5 January 2007	Praia de Fora, Palhoça, SC	coastal
1350	19 March 2007	Itapirubá, Laguna, SC	coastal
1361	26 August 2008	Praia das Palmeiras, Florianópolis, SC	unknown <sup>b</sup>
1368	12 February 2009	São José, SC	unknown <sup>b</sup>

<sup>a</sup>Classified as coastal or offshore according to vertebral formula following Costa *et al.* (2006);

<sup>b</sup>Ecotype classification was not possible due to great number of missing vertebrae, and immature or missing skull.

2000; Van Bresseem *et al.*, 2007; Simões-Lopes *et al.*, 2008; Fettuccia, 2010; Laeta *et al.*, 2010a). In spite of such efforts, we still know little about how these anomalies influence the health and performance of animals, or how frequent they are within different populations. Few studies have compared the frequencies of developmental anomalies in geographically distinct populations (genus *Sotalia*: Fettuccia, 2010; Laeta *et al.*, 2010b). Even though the bottlenose dolphin

*Tursiops truncatus* is a widely-studied cetacean species, few investigations have contributed to the understanding of bone anomalies in the species (*e.g.* Berghan and Visser, 2000; Van Bresseem *et al.*, 2007).

This paper describes cases of morphological variation and bone anomalies in the axial skeleton of the bottlenose dolphin, with emphasis on the vertebral column and considering the physical maturity of those specimens.

Ecotype classification of the data set followed Costa *et al.* (2016) and it was used to check for frequency differentiation of anomalies between the groups.

We analyzed the vertebral columns of 28 individuals of bottlenose dolphins collected along the southern coast of Brazil (Table 1; Figure 1). Specimens were normally related to beach-stranding events or accidental entangling in fishing nets, and were processed by water maceration or buried in sand. These specimens are deposited in the mammal collection of Department of Ecology and Zoology, Universidade Federal de Santa Catarina.

The regions of the vertebral column were defined following the classical system in cervical (C), thoracic (T), lumbar (L) and caudal (Ca). The thoracic region was defined according to the number of vertebral ribs and the presence of rib facets in the transverse processes of the vertebrae. For specimens with absence of vertebral ribs, we considered the thoracic and lumbar regions together (Thoraco-Lumbar, T/L) to avoid misunderstandings in classification. The first caudal vertebra was identified as the first vertebra that bears hemal arch facets on its posterior ventral margin (*e.g.* Rommel, 1990; Crovetto, 1991). According to Costa *et*

*al.* (2016), coastal and offshore bottlenose dolphins from the western South Atlantic Ocean have different vertebral formula and total number of vertebrae.

Specimens were classified in three ontogenetic groups of column maturity based on visual inspection of the degree of fusion between each epiphysis with the vertebral body. These data were combined with estimation of age by dentinal Growth Layers Groups (GLG) (*c.f.* Costa, 2009; Costa and Simões-Lopes, 2012) (Tables 2 and 3). Only specimens with more than 60% of vertebrae present in the vertebral column were considered in this study.

Macroscopic abnormalities in vertebrae and ribs of bottlenose dolphins were identified and characterized through visual inspection. The vertebral columns of the specimens were compared among themselves to determine conspicuous deviations from the shape and pattern considered normal for the anatomical structures evaluated. These include asymmetry and anomalous deviation of the spinous processes of vertebra, extranumerary articulations in ribs and fusion of cervical vertebrae. We also discuss if the cleft vertebral arch can be considered a developmental anomaly.

**Table 2.** Ontogenetic groups of vertebral column maturity based on the degree of fusion of epiphyses to the vertebral body and the estimation of age (in years) by growth layer groups.

Ontogenetic group	Description of the degree of fusion of the epiphyses along the vertebral column	Age range
1	Vertebral column without fusion of epiphyses or fusion initiating only in the cervical	0 to 2/3
2	Vertebral column with different degrees of fusion of epiphyses to the vertebral body	>2 to 11/12
3	Vertebral column with all epiphyses completely fused to the vertebral body	>11/12

**Table 3.** Dentinal age in years (based on growth layer group counts), sex and ontogenetic groups of vertebral column maturity of *Tursiops truncatus* specimens analyzed (n = 28). F = Female, M = Male and U = Unknown.

	UFSC	Sex	Age		UFSC	Sex	Age		UFSC	Sex	Age
Ontogenetic group 1	1210	U	fetus	Ontogenetic group 2	1106	U	2	Ontogenetic group 3	1350	M	11
	1361	M	0		1295	M	2.5		1317	U	12+
	1072	M	<0.5		1285	F	3.5		1322	U	12+
	1103	M	<0.5		1281	F	4		1252	U	13
	1105	M	<0.5		1126	M	4.5		1011	U	14+
	1225	M	<0.5		1099	F	5.5		1209	F	17+
	1123	M	0.5		1349	F	7		1243	U	U
	1334	F	1		1299	U	12		1287	U	U
	1368	M	3		1249	U	15+				
	1230	U	U		1261	U	U				

**Table 4.** Deviations of spinous processes of the six *Tursiops truncatus* specimens analyzed. Only vertebrae with developed spinous processes are represented. R = Right side; L = Left side; B = Both sides. Total number of vertebrae analyzed: 273.

UFSC	1	2	3	4	5	6	7	8	9	10	11	12	13	14	15	16	17
1011	-	-	-	-	-	-	-	-	-	-	-	R	-				
1243	-	-	B	B	-	-	-	R	-	L	B	B	B				
1252	-	-	-	-	-	-	-	-	-	L	L	R	R				
1261	R	-	-	-	-	-	-	-	-	-	-	-	-				
1287	-	-	-	-	-	-	R	R	R	R	R	R					
1317	-	-	-	-	-	-	-	L	-	-	R	R	-				
1011	R	R	B	B	-	-	-	-	-	-	-	-	-	-	-		
1243	B	B	-	-	-	-	-	-	-	-	-	B	B	B	B	B	B
1252	R	-	-	-	-	L	L	L	L	L	L	L	L	B	R		
1261	R	R	-	-	-	-	-	-	-	-	-	-	-	-	R	-	-
1287	B	B	B	B	L	-	R	L	B	B	B	B	B	B	B	B	B
1317	L	B	L	L	L	-	-	L	-	-	-	-	-	-			
1011	-	-	-	-	-	-	-	-	-	R	-	-	-	-	-	-	-
1243	B	B	B	L	R	-	-	R	R	-	-	-	-	-	-	-	-
1252	R	R	R	R	L	R	R	R	R	R	R	R	R	R	-	-	-
1261	-	R	L	L	-	-	-	R	-	-	-	-	-	-	-	-	-
1287	B	B	R	R	R	B	B	B	R	R	R	R	R	R	-	-	-
1317	R	R	-	R	R	R	L	L	R	L	L	L	-	-	-	-	-

#### Deviation of spinous process

The anomalous deviation and asymmetry of the dorsal end of the spinous process was observed in six of 28 specimens (UFSC 1011, 1243, 1252, 1261, 1287, and 1317), corresponding to 21% of the sample. These curvatures were observed towards the left side, the right side, or to both sides, generating a sinuous spinous process. In general, the tips of the spinous processes curving towards the right side were more frequent, corresponding to 19.8% of the 273 vertebrae analyzed (Table 4). In addition, five out of six specimens were classified as offshore (see Table 1).

With exception of the cervical region, all other regions of the vertebral column were diagnosed with anomalous deviations. The higher frequencies were registered in the lumbar and first caudal vertebrae (17.6% and 18.3% of the cases, respectively).

In particular, the specimen UFSC 1287 (n vertebrae = 65) had the highest frequency of this anatomical variation in our sample, with 36 vertebrae (55%) showing this condition (Figure 2). A high incidence was also registered in UFSC 1252 (n vertebrae = 62), with 28 vertebrae (45%) affected. All other specimens presented less than 22 vertebrae with spinous processes deviations.

Most of the affected specimens had all epiphyses fused to the vertebral body (Ontogenetic group 3), with exception of the specimen UFSC 1261, which presented different degrees of fusion (Ontogenetic group 2). It suggests that this abnormality manifests its effects on late stages of ontogenetic development and may be more frequent in highly mobile dolphins (e.g. offshore bottlenose dolphins with wider range areas).

In cetaceans, the vertebral column is the primary skeletal structure used to anchor and scaffold the muscles that generate the dorsoventral bending of the swimming movement (Long *et al.*, 1997). The relationship between vertebral structure and bending mechanics is species-specific and also varies regionally, being important in controlling the pattern of force transmission and deformation along the body-axis (Long *et al.*, 1997).

Cetaceans swim by a dorsoventral undulation of their flukes powered by the massive epaxial and hypaxial muscles (Pabst, 1990; 1993). Specifically, *m. multifidus* and *m. longissimus* have major serial attachments on the vertebral spinous processes.

Taking into consideration the importance of the spinous process as a muscle attachment site for the dorsoventral movement of the flukes, the presence of anomalous conditions

such as deviations and asymmetry would presumably, in some cases, affect the normal swimming movement. Despite the unknown longevity of the delphinids with vertebral column anomalies, Berghan and Visser (2000) demonstrated that animals with several cases of malformations (*e.g.* scoliosis, lordosis, slight lateral malformation) are able to survive for many years, depending on the extent and resulting complications of the malformations.

Crovetto<sup>2</sup> analyzed a case of vertebral asymmetry in a specimen of the blue whale *Balaenoptera musculus* and suggested that this asymmetry could be generated by compensatory remodeling of transverse processes in the lumbar and caudal regions. Furtado and Simões-Lopes (1999) and Van Bresse *et al.* (2007) also diagnosed anomalous deviations in the spinous processes of vertebrae in Atlantic spotted dolphin *Stenella frontalis* and bottlenose dolphin, respectively, but without apparent remodeling of transverse processes. Anomalous deviations of spinous processes without compensatory remodeling of transverse processes were also diagnosed in our study.

#### *Extranumerary articulation in sternal ribs*

An articulation connecting the first two sternal ribs was identified in two specimens of bottlenose dolphins (UFSC 1230 and 1349). In the juvenile specimen UFSC 1349 this anomaly is restricted to the ribs on the right side (Figure 3), while in the young specimen UFSC 1230 both sides presented this anomaly.

According to Rommel (1990) the sternum of the bottlenose dolphin articulates with three or four sternbrae. The manubrium has the first sternal rib articulating at its anterolateral margin and the next two or three sternal ribs articulate between adjacent sternbrae. The remaining sternal ribs attach via fibrous connective tissue at the posterior end of the sternum.

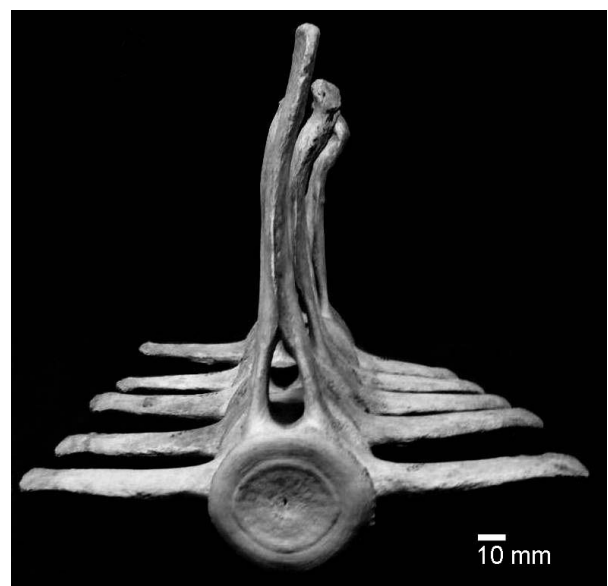
An extranumerary articulation in sternal ribs seems to be a rare phenomenon in cetaceans, with apparently no other records in the literature.

#### *Cervical abnormal fusion*

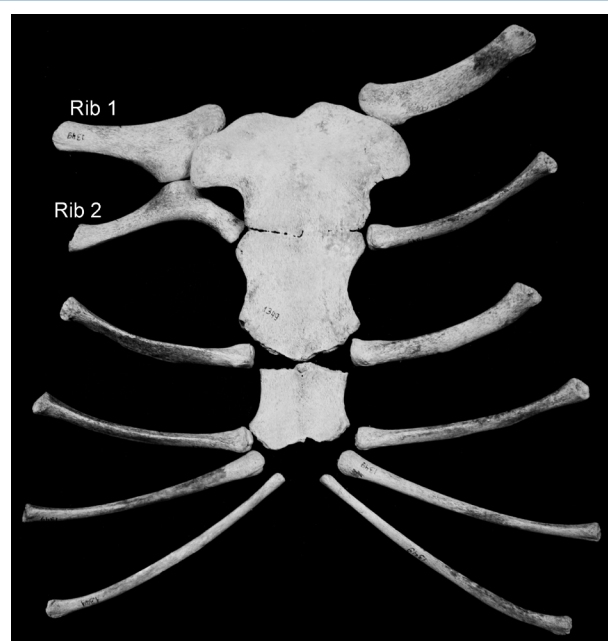
In bottlenose dolphin, the C1 and C2 (atlas and axis) are normally fused. However, abnormal fusion was diagnosed between the laminae of vertebral arches of the sixth and seventh cervical vertebrae in the adult specimens UFSC 1011 and 1322 (Figure 4). The specimen UFSC 1322 also had fused laminae of vertebral arches of the third and fourth cervical vertebrae.

Fettuccia (2010) observed the same ankylosis pattern in tucuxi *Sotalia fluviatilis*. Rommel (1990) mentioned the occasional fusion of the third cervical with the atlas-axis complex in bottlenose dolphin.

According to Fettuccia (2010), this anomaly normally occurs in association with other bone abnormalities (*e.g.* fractures, discoarthrosis, spondiloarthritis) and potentially

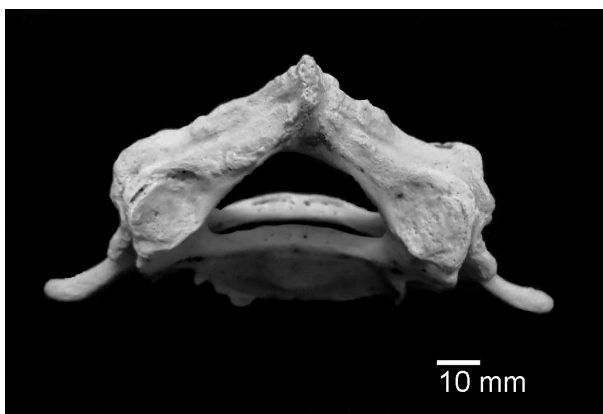

**Figure 2.** Cranial view of the deviation of spinous processes of vertebrae L13-Ca2 in the bottlenose dolphin specimen UFSC 1287. Scale bar = 10mm.

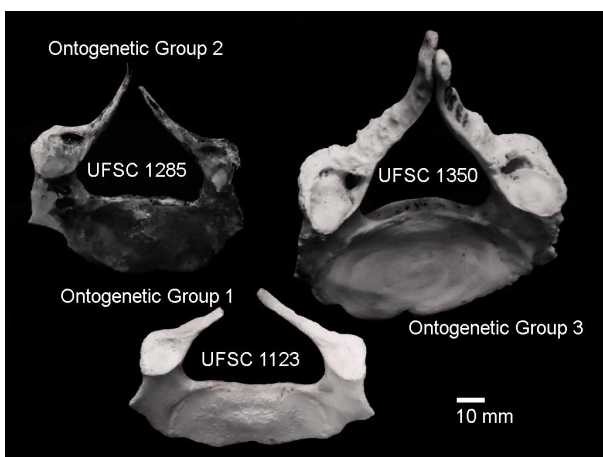


**Figure 3.** Ventral view of sternum and sternal ribs of the bottlenose dolphin specimen UFSC 1349 showing an extranumerary articulation between the first two ribs on the right side.

may hamper the natural movement of the cervical region. Cases of fractures, discoarthrosis, spondiloarthritis, and cervical ribs (as also shown in Figure 4) were previously observed in bottlenose dolphin specimens affected by cervical fusion in the present paper (*c.f.* Costa, 2009).



**Figure 4.** Dorsocranial view of C6-7 showing fusion of laminae of vertebral arches in the bottlenose dolphin specimen UFSC 1011. Scale bar = 10mm.



**Figure 5.** Cleft arch in the C7 in bottlenose dolphin specimens in different ontogenetic groups of column maturity. Scale bar = 10mm.

#### *Cleft Neural Arch*

We observed the cleft neural arch of the second, sixth and seventh cervical vertebrae on 11 out of 28 specimens of bottlenose dolphins, corresponding to 39% of the specimens analyzed (Figure 5).

Younger individuals (Ontogenetic group 1) normally presented the cleft neural arch in the C7, as observed in the specimens UFSC 1123, 1334 and 1368. The specimen UFSC 1225 had both C6 and C7 with cleft arch. Even though young individuals show a much thinner lamina, which can be broken during the preparation of the specimens, cleft neural arches produced by preparation artifacts were easily recognizable and were not accounted in our analysis.

Juveniles (Ontogenetic group 2) also presented C7 with cleft arch (specimens UFSC 1126, 1281 and 1285). In addition, specimen UFSC 1349 presented the C2 and C7 with the same abnormality. Adult specimens (Ontogenetic group 3) presented this variation in the C6 (specimen UFSC 1317) and in the C7 (specimens UFSC 1322 and 1350).

Cases of cleft arch in cervical vertebrae were previously reported for the genera *Sotalia* (Fettuccia and Simões-Lopes, 2004; Van Bressemer *et al.*, 2007; Fettuccia, 2010; Laeta *et al.*, 2010a, b) and *Stenella* (Perrin, 1975). Cowan (1966) reported cleft arches in the thoracic vertebrae of long-finned pilot whale *Globicephala melas*.

Cleft neural arches, and consequently the lack of spinous processes, can be result of a disruption in the normal prenatal development where the cartilaginous lamina of the bilateral neural arch centers do not meet and fuse (Noden and De Lahunta<sup>3</sup>, as cited by Fordyce and Watson, 1998). This condition seems to occur even in early cetaceans, having been diagnosed in lumbar vertebrae of a fossil Mysticete from the Early Oligocene (32-34 Ma) (Fordyce and Watson, 1998).

It is important to consider that not all morphological variations are necessarily examples of pathology or malformation (Ferigolo, 1987), as they may represent individual morphological variation (*e.g.* fluctuating asymmetry). Previous reports of cleft neural arches in estuarine dolphin *Sotalia guianensis* suggested that it was a developmental anomaly (see Van Bressemer *et al.*, 2007; Laeta *et al.*, 2010a, b). However, the cleft neural arch was considered normal, with a range of individual variation in the genus *Sotalia* (Fettuccia, 2010) and more specifically in C7 for the Santa Catarina population of *S. guianensis* (Fettuccia and Simões-Lopes, 2004).

In this study, the presence of cleft neural arch was observed in both offshore and coastal bottlenose dolphins, but with higher frequency in the later group. Therefore, in our opinion, cleft neural arches in small cetaceans need to be reevaluated taking into account their frequency of occurrence in different populations, allowing a better understanding if they represent true cases of anomalies or are examples of normal individual variation.

From the 28 specimens of bottlenose dolphin evaluated here, more than half (64%) showed some anatomical variation with some anomalies being more frequent in one ecotype than the other. However, further studies with larger sample size for each ecotype are necessary to better investigate differences in the frequencies of anatomical variation and bone anomalies as well as their consequences to performance and fitness of the animals.

#### **Acknowledgments**

Thanks are extended to Conselho Nacional de Desenvolvimento Científico e Tecnológico (CNPq) for financial support to A.P.B. Costa (PIBIC Scholarship) and P.C. Simões-Lopes (CNPQ/PQ Grant, process number 304698/2006-7) during the development of this study. We are grateful to R. Ewan Fordyce for comments and suggestions in early drafts of this manuscript and three anonymous reviewers for providing valuable comments to improve this article. We thank Danielle Lima for designing the study site map.

<sup>3</sup>Noden, D.M., and De Lahunta, A. (1985) *The Embryology of Domestic Animals. Developmental mechanisms and malformations*. Williams and Wilkins, Baltimore, USA. 367 pp.

## References

- Alexander, J.W., Solang, M.A. and Riegel, L.S. (1989) Vertebral osteomyelitis and suspected diskospondylitis in an Atlantic bottlenose dolphin (*Tursiops truncatus*). *Journal of Wildlife Diseases* 25(1): 118-121. <http://dx.org/10.7589/0090-3558-25.1.118>
- Berghan, J. and Visser, I.N. (2000) Vertebral column malformations in New Zealand delphinids with a review of cases worldwide. *Aquatic Mammals* 26(1): 17-25.
- Costa, A.P.B. (2009) *Variação morfológica e ontogenia da coluna vertebral e costelas de Tursiops truncatus (Cetacea, Delphinidae), do litoral de Santa Catarina*. B.Sc. Thesis. Universidade Federal de Santa Catarina. Florianópolis, Brazil. 79 pp.
- Costa, A.P.B. and Simões-Lopes, P.C. (2012) Physical maturity of the vertebral column of *Tursiops truncatus* (Cetacea) from southern Brazil. *Neotropical Biology and Conservation* 7(1): 2-7. <http://dx.doi.org/10.4013/nbc.2012.71.01>
- Costa, A.P.B., Rosel, P.E., Daura-Jorge, F.G. and Simões-Lopes, P.C. (2016) Offshore and coastal common bottlenose dolphins of the western South Atlantic face-to-face: What the skull and the spine can tell us. *Marine Mammal Science* 32(4): 1433-1457. <http://dx.doi.org/10.1111/mms.12342>
- Cowan, D.F. (1966) Pathology of the pilot whale, *Globicephala melaena*. *Archives of Pathology* 82: 178-189.
- Crovetto, A. (1991) Étude osteométrique et anatomo-fonctionnelle de la colonne vertébrale chez les grands cétacés. *Investigations on Cetacea* 23: 7-189.
- Ferigolo, J. (1987) Anatomia comparada, paleontologia e paleopatologia de vertebrados. *Paula-Coutiana* 1: 105-127.
- Fettuccia, D.C. (2010) *Ontogenia e variação osteológica das espécies do gênero Sotalia Gray, 1866 (Cetacea, Delphinidae)*. Ph.D. Thesis. Instituto Nacional de Pesquisas da Amazônia. Manaus, Brazil. 174 pp.
- Fettuccia, D.C. and Simões-Lopes, P.C. (2004) Morfologia da coluna vertebral do boto-cinza, *Sotalia guianensis* (Cetacea, Delphinidae). *Biotemas* 17(2): 125-148.
- Fordyce, R.E. and Watson, A.G. (1998) Vertebral pathology in an Early Oligocene whale (Cetacea, Mysticeti) from Wharekuri, North Otago, New Zealand. *Mainzer Naturwiss Archiv/Beiheft* 21: 161-176.
- Furtado, M.H.B.C. and Simões-Lopes, P.C. (1999) Alterações senil-degenerativas e variações anatômicas na coluna vertebral de pequenos cetáceos. *Biotemas* 12(1): 133-147.
- Galatius, A., Sonne, C., Kinze, C.C., Dietz, R. and Jensen, J.B. (2009) Occurrence of vertebral osteophytosis in a museum sample of white-beaked dolphins (*Lagenorhynchus albirostris*) from Danish waters. *Journal of Wildlife Diseases* 45(1): 19-28. <http://dx.org/10.7589/0090-3558-45.1.19>
- Kompanje, E.J.O. (1999) Considerations on the comparative pathology of the vertebrae in Mysticeti and Odontoceti: evidence for the occurrence of discarthrosis, zygarthrosis, infectious spondylitis and spondyloarthritis. *Zoologische Mededelingen Leiden* 73: 99-130.
- Laeta, M., Souza, S.M.F.M. and Siciliano, S. (2010a) Anomalias ósseas congênitas em *Sotalia guianensis* (Mammalia, Cetacea, Delphinidae) da costa centro-norte do estado do Rio de Janeiro. *Pesquisa Veterinária Brasileira* 30(6): 484-490. <http://dx.org/10.1590/S0100-736X2010000600003>
- Laeta, M., Souza, S.M.F.M. and Siciliano, S. (2010b) Cervical ribs and cleft arches in Brazilian *Sotalia guianensis*: contribution to comparative studies of skeletal morphology in northern and southeastern specimens. *Latin American Journal of Aquatic Mammals* 8(1-2): 151-165. <http://dx.doi.org/10.5597/lajam00164>
- Long, J.H., Pabst, D.A., Shepherd, W.R. and McLellan, W.A. (1997) Locomotor design of dolphin vertebral columns: bending mechanics and morphology of *Delphinus delphis*. *Journal of Experimental Biology* 200: 65-81.
- Miles, A.E. and Grigson, C. (1990) *Colyer's variation and diseases of the teeth of animals*. Cambridge University Press, Cambridge, UK. 672 pp.
- Pabst, D.A. (1990) Axial muscles and connective tissues of the bottlenose dolphin. Pages 51-67 in Leatherwood, S. and Reeves, R.R. (Eds) *The Bottlenose Dolphin*. Academic Press, San Diego, USA.
- Pabst, D.A. (1993) Intramuscular morphology and tendon geometry of the epaxial swimming muscles of dolphins. *Journal of Zoology London* 230: 159-176.
- Perrin, W.F. (1975) Variation of spotted and spinner porpoise (genus *Stenella*) in the Eastern Pacific and Hawaii. *Bulletin of the Scripps Institution of Oceanography* 21: 1-206.
- Rommel, S. (1990) Osteology of the bottlenose dolphin. Pages 29-49 in Leatherwood, S. and Reeves, R.R. (Eds) *The Bottlenose Dolphin*. Academic Press, San Diego, USA.
- Simões-Lopes, P.C., Menezes, M.E. and Ferigolo, J. (2008) Alterações senil-degenerativas, patológicas, traumáticas e malformações ósseas. Pages 39-50 in Monteiro Filho, E.L.A. (Ed.) *Biologia, ecologia e conservação do boto-cinza*. Edições Ibama, Brasília, Brazil.
- Sweeny, M.M., Price, J.M., Jones, G.S., French, T.W., Early, G.A. and Moore, M.J. (2005) Spondylitic changes in long-finned pilot whales (*Globicephala melas*) stranded on Cape Cod, Massachusetts, USA, between 1982 and 2000. *Journal of Wildlife Diseases* 41(4): 717-727. <http://dx.org/10.7589/0090-3558-41.4.717>

- Van Bresseem, M-F, Waerebeek, K.V., Reyes, J., Félix, F., Echegaray, M., Siciliano, S., Di Benedetto, A.P., Flach, L., Viddi, F., Avila, I.C., Herrera, J.C., Tobón, I.C., Bolaños-Jiménez, J., Moreno, I.B., Ott, P.H., Sanino, G.P., Castineira, E., Montes, D., Crespo, E., Flores, P.A.C., Haase, B., Souza, S.M.F.M., Laeta, M. and Fragoso, A.B. (2007) A preliminary overview of skin and skeletal diseases and traumata in small cetaceans from South American waters. *Latin American Journal of Aquatic Mammals* 6(1): 7-42. <http://dx.org/10.5597/lajam00108>
- Watson, A., Bahr, R.J. and Alexander, J.W. (2004) Thoracolumbar kyphoscoliosis and compression fracture of a thoracic vertebra in a captive bottlenose dolphin (*Tursiops truncatus*). *Aquatic Mammals* 30(2): 275-278.