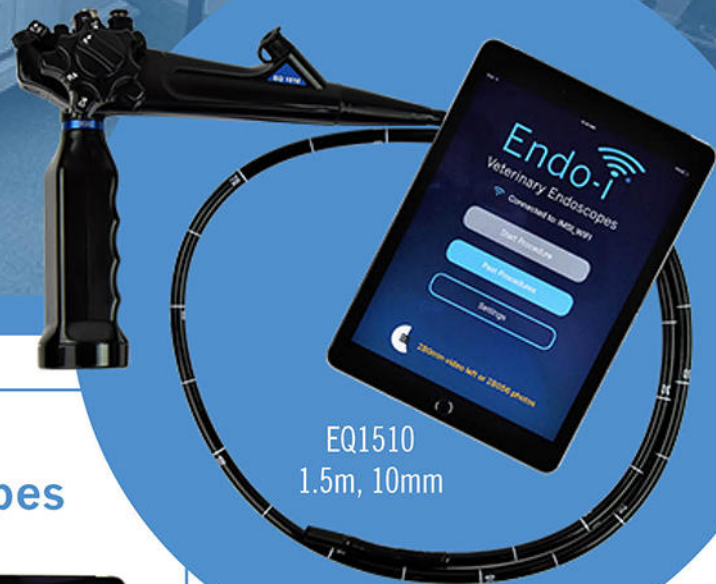

# SOMETIMES OLD SCHOOL ISN'T COOL

There's a *Better*  
Way to Scope...



EQ1510  
1.5m, 10mm

## Endo-i<sup>®</sup> Wireless HD Endoscopes

- ▶ No Bulky Towers
- ▶ Easy to Transport
- ▶ 3 Models Available (1m, 1.5m, 3m)
- ▶ Tablet & App Included



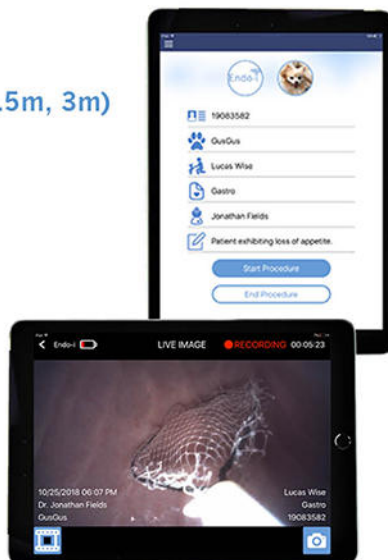
EASE-OF-USE



MANAGE PATIENT  
INFORMATION



EXPORT  
PROCEDURAL  
DATA



Patented Technology






 **STERIS**

Animal Health

1.844.540.9810  
sterisanimalhealth.com

## STANDARD ARTICLE

# Comparison of signalment and computed tomography findings in French Bulldogs, Pugs, and English Bulldogs with and without clinical signs associated with thoracic hemivertebra

Steven De Decker<sup>1</sup>  | Rowena M. A. Packer<sup>1</sup> | Rodolfo Cappello<sup>2</sup> |  
 Tom R. Harcourt-Brown<sup>3</sup>  | Cecilia Rohdin<sup>4,5</sup> | Sergio A. Gomes<sup>6</sup>  |  
 Niklas Bergknut<sup>2</sup> | Tom A. Shaw<sup>3</sup> | Mark Lowrie<sup>6</sup>  | Rodrigo Gutierrez-Quintana<sup>7</sup> 

<sup>1</sup>Department of Veterinary Clinical Science and Services, Royal Veterinary College, University of London, Hatfield, United Kingdom

<sup>2</sup>North Downs Specialist Referrals, Bletchingley, United Kingdom

<sup>3</sup>School of Veterinary Sciences, University of Bristol, North Somerset, United Kingdom

<sup>4</sup>Department of Clinical Sciences, Swedish University of Agricultural Sciences, Uppsala, Sweden

<sup>5</sup>Anicura, Albano Small Animal Hospital, Danderyd, Sweden

<sup>6</sup>Dovecote Veterinary Hospital, Derby, United Kingdom

<sup>7</sup>School of Veterinary Medicine, College of Medical, Veterinary and Life Sciences, University of Glasgow, Glasgow, United Kingdom

## Correspondence

Steven De Decker, Department of Veterinary Clinical Science and Services, Royal Veterinary College, University of London, Hawkshead Lane, North Mymms, Hatfield AL9 7TA, United Kingdom.  
 Email: sdedecker@rvc.ac.uk

## Present address

Niklas Bergknut, Faculty of Veterinary Medicine, University of Utrecht, Yalelaan 1, 3584 CL Utrecht, The Netherlands.

Tom A. Shaw, Willows Vets Veterinary Specialist Referral Service, Solihull, United Kingdom.

## Abstract

**Background:** Although thoracic hemivertebra can cause neurological signs, they occur commonly in neurologically normal dogs.

**Objectives:** To evaluate whether computed tomography (CT) findings and factors associated with signalment can be used to differentiate between dogs with and without neurological signs associated with hemivertebra.

**Animals:** One hundred sixty dogs with  $\geq 1$  hemivertebrae were retrospectively studied. This group consisted of 40 dogs with clinical signs caused by hemivertebra and 40 French Bulldogs, 40 Pugs, and 40 English Bulldogs that underwent CT for reasons unrelated to neurological disease.

**Methods:** All dogs underwent CT and affected dogs also underwent magnetic resonance imaging. All CT studies were randomly evaluated by an observer blinded to signalment and clinical status. The following variables were evaluated: presence, number, location, and subtype of hemivertebra; presence of vertebral subluxation; severity of vertebral canal stenosis; presence, location, and severity of kyphosis, and number of vertebrae involved in the kyphotic segment. Statistical modeling was performed to identify factors associated with clinical status.

**Results:** Pug breed (odds ratio [OR], 10.8;  $P = .01$ ), more severe kyphosis (OR, 1.1 per grade increase;  $P < .001$ ), fewer instead of more observed hemivertebrae (OR, 0.8;  $P = 0.03$ ), and ventrolateral hypoplasia hemivertebra subtype (OR, 4.0;  $P = .011$ ) were associated with higher likelihood of neurological disease. A Cobb angle of 34.5 degrees corresponded with the highest combined sensitivity and specificity to differentiate between clinically affected and unaffected dogs.

**Abbreviations:** AUC, area under the curve; CT, computed tomography; ID, identification; LA, lateral aplasia; LH, lateral hypoplasia; MRI, magnetic resonance imaging; ROC, receiver operating characteristic; SH, symmetrical hypoplasia; VA, ventral aplasia; VH, ventral hypoplasia; VLA, ventrolateral aplasia; VLH, ventrolateral hypoplasia; VMA, ventral and median aplasia; VMH, ventral and median hypoplasia.

This is an open access article under the terms of the Creative Commons Attribution-NonCommercial License, which permits use, distribution and reproduction in any medium, provided the original work is properly cited and is not used for commercial purposes.

© 2019 The Authors. *Journal of Veterinary Internal Medicine* published by Wiley Periodicals, Inc. on behalf of the American College of Veterinary Internal Medicine.

**Conclusions and Clinical Importance:** The variables identified could aid in differentiating between clinically relevant and irrelevant hemivertebra in small breed brachycephalic dogs.

**KEYWORDS**

brachycephalic, kyphosis, screw-tailed, spinal malformation, vertebral malformation

## 1 | INTRODUCTION

The popularity of small brachycephalic dog breeds has surged in recent years. The French Bulldogs, Pugs, and English Bulldogs all were listed among the 10 most popular registered dog breeds in the United Kingdom for 2018.<sup>1</sup> Because dogs of these breeds can have a curly tail, they are sometimes referred to as “screw-tailed” brachycephalic breeds. The mechanisms resulting in this characteristic curly tail, however, are possibly different among breeds.<sup>2,3</sup> Their increase in popularity has been associated with welfare concerns associated with their anatomical conformation.<sup>4,5</sup> “Screw-tailed” brachycephalic dogs are prone to suffer from breathing problems, ophthalmologic disorders, skin disease, and several spinal conditions.<sup>6,7</sup> One type of spinal condition often associated with this group of dogs is congenital vertebral body malformation.<sup>8</sup> Although the terminology and classification are debated, hemivertebra are considered a common type of congenital vertebral body malformation.<sup>9</sup> Thoracic hemivertebrae occur commonly in clinically normal small breed brachycephalic dogs and therefore should be considered incidental imaging findings in the majority of dogs in which they are identified.<sup>8,10-15</sup> Hemivertebrae can be associated with an abnormal dorsal (ie, kyphosis) or lateral (ie, scoliosis) curvature of the vertebral column and have the potential to alter spinal biomechanics, contribute to degenerative spinal conditions, or result directly in clinical signs of spinal cord dysfunction.<sup>15-19</sup> Although the pathophysiology of development of clinical signs in dogs with hemivertebra is not completely known, it is considered to be multifactorial with static and dynamic factors involved.<sup>10,16</sup> Dogs with clinically relevant thoracic hemivertebrae most often develop slowly progressive clinical signs in the first year of life.<sup>16</sup> Treatment of thoracic hemivertebra is challenging with results of medical management considered to be unfavorable<sup>20</sup> and surgical techniques, although associated with good outcomes, considered technically demanding.<sup>21-23</sup> Although several studies have suggested individual risk factors for development of clinical signs,<sup>8,10-12</sup> it remains difficult to differentiate between clinically relevant and irrelevant thoracic hemivertebrae. The pug breed, hemivertebra subtype, presence of subluxation, and severity of kyphosis have, in different studies, been associated with a higher likelihood of development of neurological signs.<sup>8,10-12</sup> None of these factors can, however, solely be relied upon to identify clinically affected dogs. This is illustrated by the fact that severe kyphosis also can be seen in clinically normal dogs<sup>15,18,24</sup> and that not all Pugs with thoracic hemivertebra will develop neurological signs.<sup>8,15</sup> It is further unknown which of these factors should be considered the strongest indicators of clinical disease. Our aim

therefore was to compare the signalment and computed tomography (CT) findings of French Bulldogs, Pugs, and English Bulldogs with and without clinical signs associated with thoracic hemivertebra. It was hypothesized that several variables, including Pug breed and more severe kyphosis, would be associated with clinical signs in dogs with hemivertebra.

## 2 | MATERIALS AND METHODS

This retrospective descriptive cross-sectional study was approved by the institutional ethics and welfare committee (SR2018-1662). The digital medical databases of 5 specialist referral centers were reviewed between April 14, 2010, and March 12, 2018, to identify French Bulldogs, Pugs, and English Bulldogs with neurological signs caused by thoracic hemivertebra. Search terms included hemivertebra, vertebral malformation, kyphosis, and kyphoscoliosis. Dogs were included if medical records and imaging studies were available and if a diagnosis was made by a combination of CT and magnetic resonance imaging (MRI). To be included, readily apparent spinal cord compression with or without an intraparenchymal T2-weighted hyperintensity had to be present at the site of the hemivertebra. Dogs were excluded if a diagnosis was not made by a combination of CT and MRI, if the imaging studies were not available for review, or if any other abnormalities were detected on MRI and clinical signs therefore could not solely be attributed to thoracic hemivertebra. Dogs with concurrent spinal abnormalities, such as a spinal arachnoid diverticulum, constrictive myelopathy, or an intervertebral disc protrusion therefore were not included in the study. The medical records and imaging studies were evaluated by 1 of the study authors to determine study eligibility. Information retrieved from the medical records included signalment as well as duration and type of clinical signs. Thoracic CT was performed using a dual slice, 16-slice, or 128-slice helical scanner. After completion of the axial CT study, sagittal, dorsal, and 3-dimensional reconstructions were made. Magnetic resonance imaging was performed using a 0.2, 0.25, or 1.5 Tesla magnet and included a minimum of T2- and T1-weighted sagittal and transverse images. Standard image archiving and communication system software (Horos, version 2.0.2., [www.horosproject.org](http://www.horosproject.org)) was used to evaluate all imaging studies.

After the imaging studies of dogs with clinically relevant thoracic hemivertebra were collected, the digital medical database of 1 of the participating centers was searched for French Bulldogs, Pugs, and English Bulldogs that underwent CT for reasons unrelated to neurologic or orthopedic disease. Some of these CT studies also were

included in a previous study.<sup>24</sup> All CT studies were evaluated by the same study author who had evaluated the imaging studies of the clinically affected dogs. Only CT studies of dogs that had  $\geq 1$  hemivertebrae were considered for further inclusion. Finally, for each of the 3 breeds, a number of CT studies equal to the total number of clinically affected dogs was randomly selected. All CT studies were performed under sedation or general anesthesia with a 16-slice helical CT scanner. The majority of these dogs had not received a neurological examination. They were considered neurologically normal if they were evaluated for a non-neurological condition and if none of the clinical notes mentioned any previous or current abnormalities in gait or neurological status. Information retrieved from the medical records included signalment and reason for presentation.

All CT studies (neurologically affected and unaffected dogs) were anonymized and presented in a randomized order to a board-certified neurologist who was not involved in previous patient selection. Randomization was performed by using an online available random list generator ([www.random.org](http://www.random.org)), and the reviewer was unaware of signalment and clinical status of each dog. The MRI studies were not presented to this observer. For each imaging study, the presence, number, and location of hemivertebrae were assessed, and each hemivertebra was categorized into 1 of 9 subtypes as reported previously.<sup>24</sup> The presence of vertebral subluxation; the remaining vertebral canal area at the level of each hemivertebra; and the presence, location, degree of kyphosis, and number of vertebrae involved in the kyphotic segment also were recorded. Abnormalities of the dorsal arch (ie, articular processes, dorsal lamina, and spinous process) were not evaluated.

Hemivertebra subtypes included ventral aplasia (VA) or dorsal hemivertebra, ventral hypoplasia (VH) or ventral wedge-shape vertebra, lateral aplasia (LA) or lateral hemivertebra, lateral hypoplasia (LH) or lateral wedge-shape vertebra, ventrolateral aplasia (VLA) or dorsolateral hemivertebra, ventrolateral hypoplasia (VLH), ventral and median aplasia (VMA) or butterfly vertebra, ventral and median hypoplasia (VMH), and symmetrical hypoplasia (SH) or short vertebra.<sup>24</sup> Vertebral subluxation was defined as dorsal displacement of a vertebra with step formation between the dorsal aspect of 2 adjacent vertebrae.<sup>10</sup> The remaining vertebral canal area was determined to quantify the extent of vertebral canal stenosis at the level of each hemivertebra. It was calculated by dividing the transverse vertebral canal area at the center of the hemivertebra by the average transverse vertebral canal area of the unaffected cranial and caudal vertebrae and multiplied by 100.<sup>25</sup> A value of 100 would represent no vertebral canal stenosis, whereas a value of 0 would represent complete vertebral canal stenosis. Severity of dorsal curvature was evaluated by determining the Cobb angle, which was measured automatically using a commercial plug-in device as described previously.<sup>12</sup> For the purpose of this study, kyphosis was defined as a dorsal spinal curvature with a Cobb angle  $>10$  degrees.<sup>21,26</sup> The location of kyphosis along the vertebral column was defined by the location of the 2 most central vertebrae in the kyphotic segment. If multiple hemivertebrae were present, kyphosis was measured at the most severely affected site.

## 2.1 | Statistical methods

Statistical analysis was performed by 1 of the authors, and the data were analyzed using statistical software (IBM SPSS Statistics version 19, New York). The binary outcome variable was a diagnosis of clinical signs associated with hemivertebra. Associations between the predictor variables (signalment and CT characteristics) and the outcome variable were screened at the univariable level using binary logistic regression modeling for dog-related variables (eg, signalment, number of hemivertebrae, presence of kyphosis), and generalized linear mixed models for hemivertebra-related variables (eg, location, type, vertebral canal diameter) to allow for the random effect of dog identification (ID) to be taken into account.<sup>27</sup> Variables liberally associated with a diagnosis of clinical signs associated with hemivertebra at the univariable level ( $P < .2$ ) were taken forward to be tested in a multivariable model, a generalized linear mixed multivariate model with a diagnosis of clinically relevant hemivertebra as the binomial outcome variable. Dog ID was included as a random effect in all models to account for this source of non-independence (introduced by multiple hemivertebrae per dog being included in the analyses). Multivariable model development used manual backwards stepwise elimination ( $P < .05$  cutoff).<sup>28</sup> Odd ratios (OR) of significant variables were inspected to determine if clinical signs were more or less likely to occur in association with each variable. Multicollinearity was evaluated in all models, identified from inflated SEs in the models and thus avoided.

In addition to these analyses, a post hoc receiver operating characteristic (ROC) analysis was used to examine the Cobb angle, expressing the extent of kyphosis, as an indicator for the presence of clinical signs caused by hemivertebra, by determining the diagnostic power of the test by measuring the area under the curve (AUC). A perfect test has an AUC value of 1.0, and an AUC of 0.5 means the test performs no better than chance. Youden's index (Youden's statistic;  $J = \text{sensitivity} + [\text{specificity} - 1]$ ) was calculated to identify the optimal cutoff value of Cobb angle that yielded maximum sums from the ROC curve.<sup>29</sup>

## 3 | RESULTS

One hundred sixty dogs with  $\geq 1$  thoracic hemivertebrae were included in the study. This group consisted of 40 dogs with clinical signs caused by hemivertebra and 40 French Bulldogs, 40 Pugs, and 40 English Bulldogs that underwent CT for reasons unrelated to neurological or orthopedic disease.

### 3.1 | Clinically affected dogs

This group consisted of 31 Pugs, 7 French Bulldogs, and 2 English Bulldogs aged 3 months to 9 years 4 months (median, 11 months). Twenty-five males (4 neutered) and 15 females (3 neutered) were included in this group. Duration of clinical signs ranged from 1 day to 2 years (median, 25 days) and consisted of ambulatory paresis and ataxia of the pelvic limbs in 39 dogs and paraplegia with intact nociception in 1 dog. Spinal hyperesthesia was detected in 4 dogs, and 2 dogs had urinary and fecal incontinence.

A total of 94 hemivertebrae with a median of 2 hemivertebrae per dog were diagnosed in this group of dogs. A single hemivertebra was present in 13 dogs (32%), 2 hemivertebrae in 13 dogs (32%), 3 hemivertebrae in 8 dogs (20%), and  $\geq 4$  hemivertebrae were present in the remaining 6 dogs (15%). The most common hemivertebra subtype was VH ( $n = 24$ , or 26% of all diagnosed hemivertebrae; present in 20 dogs [50% of dogs]), followed by VA ( $n = 20$ , or 21%; present in 20 dogs [50%]), SH ( $n = 14$ , or 15%; present in 8 dogs [20%]), VMH ( $n = 13$ , or 14%; present in 6 dogs [15%]), VMA ( $n = 10$ , or 11%; present in 5 dogs [12%]), VLH ( $n = 9$ , or 10%; present in 6 dogs [15%]), VLA ( $n = 3$ , or 3%; present in 2 dogs [5%]), and LA ( $n = 1$ , or 1%; present in 1 dog [2%]). The most commonly affected vertebra was T8 ( $n = 28$ , or 30% of all hemivertebrae), followed by T7 ( $n = 24$ , or 26%), T6 ( $n = 10$ , or 11%), T4 and T9 ( $n = 9$ , or 10% for both), T10 ( $n = 4$ , or 4%), T5 ( $n = 3$ , or 3%), T11, T12, and T13 ( $n = 2$ , or 2% for each), and T2 ( $n = 1$ , or 1%). The Cobb angle varied from 7 to 89 degrees (median, 59 degrees) with all but 1 dog (98%) having kyphosis. The number of vertebrae included in the kyphotic segment varied from 2 to 7 (median, 3 vertebrae), and the center of the kyphotic segment most often was located at the level of the T7 and T8 vertebrae (28 dogs or 72% of dogs with kyphosis). Subluxation was present in 33 dogs (82%). The remaining vertebral canal diameter at the location of each hemivertebra varied from 28% to 100% (median, 72%).

### 3.2 | Clinically unaffected dogs

This group consisted of 40 French Bulldogs, 40 Pugs, and 40 English Bulldogs aged 4 months to 13 years 3 months (median, 2 years 2 months). Seventy-six males (35 neutered) and 44 females (25 neutered) were included in this group. All dogs underwent CT for a variety of clinical indications, including brachycephalic obstructive airway syndrome ( $n = 92$ ), neoplasia ( $n = 14$ ), other respiratory disease ( $n = 12$ ), and cardiac disease ( $n = 2$ ).

A total of 411 hemivertebrae with a median of 3 hemivertebrae per dog were diagnosed in this group of dogs. A single hemivertebra was present in 25 dogs (21%), 2 hemivertebrae in 32 dogs (27%), 3 hemivertebrae in 18 dogs (15%), and  $\geq 4$  hemivertebrae were present in the remaining 45 dogs (37%). The most common hemivertebra subtype was VMH ( $n = 147$ , or 36% of all diagnosed hemivertebrae; present in 68 dogs [57% of dogs]), followed by VMA ( $n = 93$ , or 23%; present in 53 dogs [44%]), SH ( $n = 67$ , or 16%; present in 41 dogs [34%]), VLH ( $n = 39$ , or 9%; present in 30 dogs [25%]), VH ( $n = 38$ , or 9%; present in 35 dogs [29%]), VLA ( $n = 20$ , or 5%; present in 14 dogs [12%]), LA ( $n = 3$ , or 0.7%; present in 3 dogs [2%]), LH ( $n = 3$ , or 0.7%; present in 2 dogs [2%]), and VA ( $n = 1$ , or 0.2%; present in 1 dog [1%]). The most commonly affected vertebra was T8 ( $n = 63$ , or 15% of all hemivertebrae), followed by T7 ( $n = 60$ , or 15%), T6 ( $n = 51$ , or 12%), T9 ( $n = 47$ , or 11%), T10 ( $n = 40$ , or 10%), T5 ( $n = 38$ , or 9%), T11 ( $n = 26$ , or 6%), T4 ( $n = 25$ , or 6%), T12 ( $n = 22$ , or 5%), T13 ( $n = 15$ , or 4% for each), T3 ( $n = 11$ , or 3%), T2 ( $n = 9$ , or 2%), and T1 ( $n = 4$ , or 1%). The Cobb angle varied from 1 to 70 degrees (median, 9 degrees) with 58 dogs having kyphosis. The number of vertebrae included in the kyphotic segment varied from 2 to 6 (median,

3 vertebrae) and the center of the kyphotic segment most often was located at the level of the T10 and T11 vertebrae (25 dogs or 43% of the dogs with kyphosis). Subluxation was present in 21 dogs (18%). The remaining vertebral canal diameter at the location of each hemivertebra varied from 33% to 100% (median, 96%).

### 3.3 | Comparison between clinically affected and unaffected dogs

Neurologically unaffected dogs were significantly older and were more often neutered ( $P < .001$  for both variables) than dogs with neurological signs. Univariate statistical analysis indicated that Pugs ( $P < 0.001$ ) compared to the French or English Bulldogs, being intact instead of neutered ( $P = .001$ ), having fewer instead of more hemivertebrae ( $P = .011$ ), hemivertebra at the level of T8 compared to T9 ( $P = .05$ ), presence of kyphosis, a higher Cobb angle, presence of subluxation, and a lower remaining vertebral canal area were associated with clinical signs caused by hemivertebra ( $P < .001$  for each). Hemivertebra subtype also was associated with the presence of neurological signs; SH ( $P = .04$ ), VA and VH ( $P < .001$  for both), and VLH ( $P = .04$ ) had a higher likelihood of clinical signs, whereas LA hemivertebra subtype was less likely to be associated with clinical signs ( $P = .04$ ).

After performing multivariable analysis, the following variables were retained as independent predictors of clinical signs associated with thoracic hemivertebra: the Pug compared to the French or English Bulldog ( $P = .01$ ), fewer instead of more of hemivertebrae ( $P = .03$ ), VLH hemivertebra subtype compared to VMH subtype ( $P = .011$ ), and a higher Cobb angle ( $P < .001$ ) were associated with an increased likelihood of clinical signs. With each increase in Cobb angle, there was a significantly increased likelihood of clinical signs (OR of 1.1 for each increase in 1 grade) associated with hemivertebra (Table 1). An ROC analysis (Figure 1) indicated that a Cobb angle of 34.5 degrees was associated with the highest combined sensitivity (85%) and specificity (93%) to differentiate between dogs with and without neurological signs. The AUC was 0.95 (95% CI, 0.91-0.98;  $P < .001$ ).

Significant associations were found between hemivertebra subtype and breed, Cobb angle, and remaining vertebral canal area. Ventral aplasia, VH, and SH subtypes were associated with Pugs ( $P < .001$ ). The majority (85.7%) of all hemivertebrae of the VA subtype was seen in Pugs. Lateral aplasia hemivertebra subtype was associated with French Bulldogs ( $P < .001$ ) with all hemivertebrae of this subtype seen in this breed. Ventral aplasia hemivertebra subtype was associated with the highest Cobb angle (median, 61 degrees; 25th and 75th percentiles, 52.5 and 68.0 degrees) and the lowest (most stenotic) remaining vertebral canal area ( $P < .001$ ; Figure 2).

## 4 | DISCUSSION

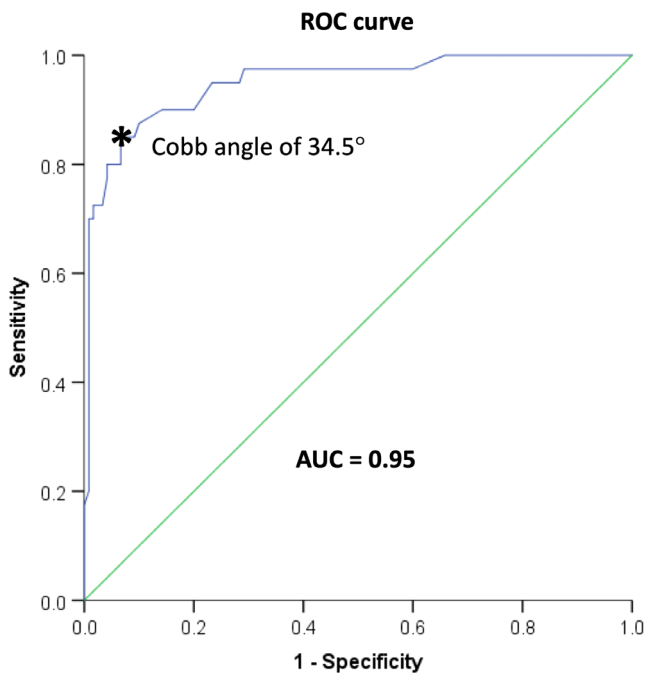
We compared the signalment and CT findings of 3 small brachycephalic breeds with and without clinically relevant thoracic hemivertebra. Several variables were identified that were associated with an increased likelihood of neurological signs: the Pug breed, higher degree of

**TABLE 1** Results of a generalized linear mixed multivariate model of predictors of neurological signs in 160 dogs with thoracic hemivertebra

Variable	Subcategory	Statistical tests		
		OR	SE	P-value
Intercept	...	0.02 (0.01-0.14)	1.12	<.001
Breed	Pug	10.8 (1.7-69.5)	2.39	.01*
	French Bulldog	2.2 (0.9-5.3)	0.43	.06
	English Bulldog	Reference		
Number of hemivertebrae	...	0.8 (0.7-0.9)	0.08	.03*
Cobb angle	...	1.1 (1.0-1.1)	0.01	<.001*
Hemivertebra subtype	Short vertebra	0.3 (0.0-1.7)	0.98	.16
	Ventral aplasia	2.2 (0.1-34.8)	1.41	.58
	Ventral hypoplasia	0.1 (0.0-1.1)	1.04	.06
	Lateral aplasia	2.4 (0.2-36.2)	1.39	.54
	Lateral hypoplasia	0.0 (0.0-0.0)	694.9	.99
	Ventrolateral aplasia	0.5 (0.1-4.9)	1.1	.58
	Ventrolateral hypoplasia	4.0 (1.4-11.8)	0.55	.01*
	Ventral and median aplasia	1.2 (0.4-3.1)	0.49	.74
	Ventral and median hypoplasia	Reference		

Dog ID is included as a random effect to account for this source of nonindependence. Significant *P*-values ( $P < .05$ ) are indicated by asterisks (\*). The Pug breed, fewer number of diagnosed hemivertebrae, higher Cobb angles, and ventrolateral hypoplasia hemivertebra subtype are considered independent predictors for the presence of clinical signs associated with thoracic hemivertebra.

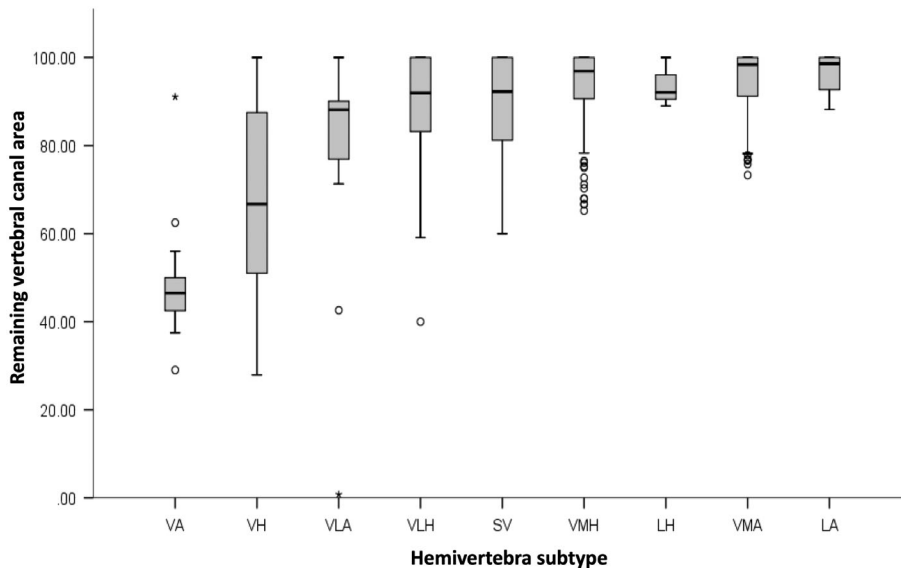
Abbreviations: OR, odds ratio; SE, standard error.



**FIGURE 1** Receiver operating characteristic curve for the degree of kyphosis expressed by the Cobb angle in 40 dogs with neurological signs associated with thoracic hemivertebra and 120 dogs without neurological signs associated with hemivertebra. A Cobb angle of 34.5 degrees (asterisk) corresponded with the highest combined sensitivity and specificity to differentiate between dogs with and without clinical signs

kyphosis, fewer instead of more observed hemivertebrae, and VLH hemivertebra subtype were considered independent variables predicting the presence of neurological signs. The identification of these variables potentially could aid in making a diagnosis and increase our understanding of the pathophysiology of hemivertebra in small breed brachycephalic dogs.

Breed was 1 of the strongest independent variables to predict the presence of neurological signs in dogs with thoracic hemivertebra. Pugs with hemivertebra were at 10-fold the odds to have neurological signs compared to French and English Bulldogs with hemivertebra. This finding suggests that Pugs are predisposed to neurological signs caused by thoracic hemivertebra, which is in agreement with previous suggestions.<sup>8</sup> A previous study found that although thoracic hemivertebrae occur less commonly in neurologically normal Pugs compared to neurologically normal French and English Bulldogs, they were paradoxically more often diagnosed with hemivertebra as the cause of neurological signs.<sup>8</sup> Although hemivertebra in neurologically normal Pugs is associated with different anatomical characteristics and a higher likelihood of kyphosis compared to hemivertebra in French and English Bulldogs,<sup>24</sup> it is currently unclear why a thoracic hemivertebra in Pugs is more likely to result in clinical signs compared to other breeds. Although these findings suggest that the occurrence of thoracic hemivertebra in Pugs should be considered of greater clinical importance, it is possible that hemivertebra in other “screw-tailed” brachycephalic breeds should not be considered a benign incidental finding on diagnostic imaging studies. Hemivertebra with kyphosis has been suggested to



**FIGURE 2** Box-Whisker plot illustrating the association between hemivertebra subtype and remaining vertebral canal area in 160 dogs with a total of 505 hemivertebrae. Ventral aplasia hemivertebra subtype was significantly associated with the smallest (most stenotic) remaining vertebral canal area (indicated by asterisk). LA, lateral aplasia; LH, lateral hypoplasia; SV, short vertebra; VA, ventral aplasia; VH, ventral hypoplasia; VLA, ventrolateral aplasia; VLH, ventrolateral hypoplasia; VMH, ventral and median hypoplasia; VMA, ventral and median aplasia

alter spinal biomechanics,<sup>17,19,30</sup> which could accelerate or contribute to the development of degenerative changes along the vertebral column, including intervertebral disk degeneration and herniation.<sup>17,18,30</sup>

In agreement with findings of previous studies, our results suggest that the severity of kyphosis should be considered a reliable indicator for the presence of neurological signs caused by hemivertebra.<sup>9,12</sup> Our study identified an almost identical cutoff value for the Cobb angle as suggested previously.<sup>12</sup> In our study, a Cobb angle of 34.5 degrees corresponded with the highest combined sensitivity and specificity to differentiate between neurologically affected and unaffected dogs. Spinal kyphosis has been implied to alter the biomechanical properties of the vertebral column.<sup>17,19,30</sup> Although the pathophysiology of clinically relevant hemivertebra is uncertain and should most likely be considered multifactorial, vertebral instability has been suggested to play an important role.<sup>10,16</sup> This is illustrated by several studies demonstrating good treatment outcomes after vertebral stabilization without spinal decompression in dogs with hemivertebra.<sup>22,23</sup> Our study supports the hypothesis that vertebral instability associated with severe kyphosis could play an important role in development of neurological signs. It should be emphasized, however, that severe degrees of kyphosis, >35 degrees, also occurred in clinically unaffected dogs and that not all affected dogs had kyphosis >35 degrees or failed to display kyphosis at all. This observation complicates generalization of diagnostic guidelines and emphasizes the multifactorial nature of the pathophysiology of thoracic hemivertebra. Treatment recommendations, therefore, can be different among individual cases with neurological signs caused by thoracic hemivertebra.

In agreement with results of a previous study, our study failed to identify a primary role for vertebral canal stenosis in the pathophysiology of clinically relevant hemivertebra.<sup>10</sup> Vertebral canal stenosis, however, was associated with hemivertebra subtype, with VA or dorsal hemivertebra resulting in the narrowest vertebral canal compared to other hemivertebra subtypes (Figure 2).

Hemivertebra subtype, more specifically VLH compared to VMH subtype, was associated with a higher likelihood of clinical signs. This result is difficult to explain because VLH can be considered to represent a rather mild degree of vertebral body malformation and is unlikely to result in kyphosis.<sup>24</sup> Previous studies have found a high prevalence of dorsal hemivertebra or VA hemivertebra subtype in dogs with clinically relevant hemivertebra.<sup>11,22</sup> Ventral aplasia is characterized by the complete absence of the vertebral body and therefore can result in severe kyphosis.<sup>11,31</sup> In agreement with previous studies, VA hemivertebra subtype occurred very rarely in dogs without clinical signs and was almost always associated with the presence of neurological signs.<sup>11,22</sup> Despite the subjective observation that VA could be of great clinical importance, our results did not identify this hemivertebra subtype as an independent predictor of clinical signs in dogs with hemivertebra. This unexpected result most likely can be explained by the fact that VA was significantly associated with Pugs (85.7% of VA hemivertebrae were seen in Pugs) and with more severe degrees of kyphosis (median Cobb angle of 61 degrees), which were considered primary factors to predict clinical signs in dogs with hemivertebra. It should further be emphasized that VA occurred only in half of the dogs with clinical signs associated with hemivertebra.

The presence of fewer rather than a higher number of hemivertebrae along the vertebral column was more likely associated with neurological signs. This finding is somewhat surprising and in contrast to regionally proposed breeding guidelines in which allocation of a more severe grade is based on a higher number of radiographically detected vertebral malformations.<sup>32</sup> As suggested above, hemivertebrae are more likely to cause clinical signs when they substantially change the anatomical and biomechanical characteristics of the vertebral column. A larger number of hemivertebrae, therefore, will not necessarily cause clinical signs if they are not associated with substantial anatomical alterations of the vertebral column, such as kyphosis (Figure 3).

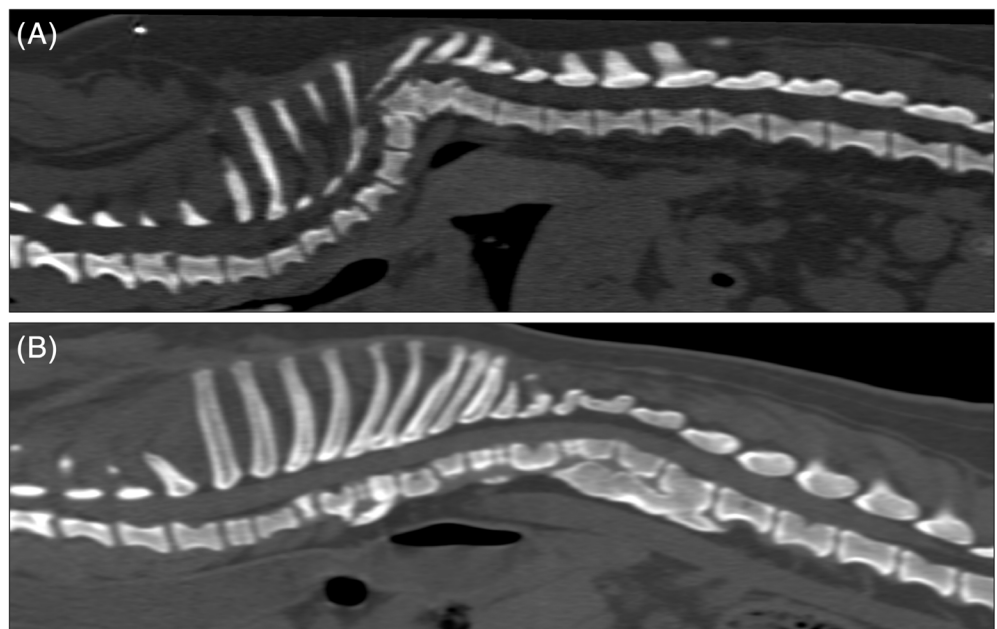
Evidence-based breeding strategies for hemivertebra are advocated to increase the likelihood of clinically unaffected offspring (if the variables identified are found to be inheritable), while decreasing the number of clinically unaffected dogs that may be lost from gene pools based on existing breeding guidelines. However, this approach is not without challenges. Although we identified several CT characteristics that are independently associated with the presence of clinical signs in dogs with thoracic hemivertebrae, caution should be exercised when considering these factors for radiographic screening programs. The prevalence of thoracic hemivertebra in neurologically normal French and English Bulldogs has been estimated to be 93.5% and 73.2%, respectively.<sup>8</sup> This extremely high prevalence of hemivertebra in clinically unaffected dogs in combination with the low prevalence of clinical disease complicates designing a meaningful screening program for these 2 breeds. Measurement of Cobb angles is an easy and reliable method of measuring the degree of kyphosis.<sup>12,33</sup> The results of our study confirm that a Cobb angle of 35 degrees is associated with the highest combined sensitivity and specificity to differentiate between clinically affected and unaffected dogs.<sup>12</sup> It seems however unlikely that measurement of Cobb angles can reliably be used in radiographic screening programs because (1) Cobb angles >35 degrees also occur in clinically normal dogs,<sup>15,18,24</sup> (2) some dogs with neurological signs associated with hemivertebra do not display kyphosis,<sup>20</sup> and (3) spinal kyphosis should not be considered a static anatomical factor and has been considered to be progressive in nature. This is illustrated in a recent case report describing neurological signs and marked thoracic kyphosis in a 6-month-old Pug. Thoracic radiographs did however not disclose any kyphosis when the dog was only 2 months old.<sup>34</sup> Kyphosis also has been reported to progress in dogs treated medically for thoracic hemivertebra.<sup>20</sup>

Our study was limited by several factors. Because of the retrospective study design, dogs included in the neurologically unaffected group did not undergo neurological examination. They were

considered neurologically normal when they underwent CT for reasons unrelated to neurological disease and when the medical files did not mention any gait abnormality. It therefore cannot be excluded that these dogs may have had mild gait abnormalities because of their vertebral malformations. The dogs in this group also did not undergo MRI. It therefore cannot be excluded that some of these dogs had spinal cord compression associated with their vertebral malformation. Although the unaffected dogs were significantly older than dogs with neurological signs, it cannot be excluded that some dogs will develop clinical signs associated with thoracic hemivertebra later in life. A recent study reported a median age of 88 months for Pugs with thoracic and lumbar vertebral malformations to develop neurological deficits.<sup>15</sup> This is remarkably older than the median age of 11 months in our study and can very likely be explained by the fact that our study focused specifically on clinical signs caused by hemivertebra. Although the blinded observer compared CT studies of dogs with and without clinical signs of thoracic hemivertebrae, it is clear that CT cannot reliably be used to obtain a final diagnosis of clinically relevant hemivertebra. There was considerable overlap between findings on CT studies of clinically affected and unaffected dogs and CT does not allow visualization of spinal cord compression, intraparenchymal spinal abnormalities, or other spinal disorders that can be seen in conjunction with vertebral body malformations, such as spinal arachnoid diverticula.<sup>35</sup> Different CT scanners were used in the clinically affected dogs. It cannot be excluded that this influenced the blinded observer's assessment. It should further be emphasized that our study evaluated a single specific cause of kyphosis: kyphosis caused by vertebral body malformations. Other causes of kyphosis, such as dorsal arch abnormalities, trauma, and intervertebral disk disease<sup>36</sup> were not evaluated, and it is therefore unclear if our results can be extrapolated to all dogs with kyphosis.

Our study identified several variables that could be used as independent factors to predict the presence of neurological signs in small breed brachycephalic dogs with thoracic hemivertebra. Our results

**FIGURE 3** Sagittal reconstructed computed tomography studies of (A) an 11-month-old Pug with neurological signs associated with hemivertebra and (B) a 2-year-old English Bulldog without neurological signs. (A) The Pug with neurological signs has only 2 hemivertebrae, which are associated with severe kyphosis. (B) Although the English Bulldog has multiple hemivertebrae, they are not associated with severe kyphosis





confirmed that Pugs and a severe degree of kyphosis should be considered the most important factors when considering a diagnosis of clinically relevant thoracic hemivertebra. Our results further determined that fewer as opposed to more hemivertebrae along the vertebral column more often are associated with clinical signs, whereas the association between hemivertebra subtypes and neurological signs remains unclear. Our result support the hypothesis that the pathophysiology of thoracic hemivertebra is multifactorial with several factors influencing each other's presence. Further studies are needed to evaluate the diagnosis, pathophysiology, and treatment of thoracic hemivertebra in "screw-tailed" brachycephalic dogs.

#### CONFLICT OF INTEREST DECLARATION

Authors declare no conflict of interest.

#### OFF-LABEL ANTIMICROBIAL DECLARATION

Authors declare no off-label use of antimicrobials.

#### INSTITUTIONAL ANIMAL CARE AND USE COMMITTEE (IACUC) OR OTHER APPROVAL DECLARATION

This study was approved by the Royal Veterinary College Social Sciences Research Ethical Review Board (SR2018-1662).

#### HUMAN ETHICS APPROVAL DECLARATION

Authors declare human ethics approval was not needed for this study.

#### ORCID

Steven De Decker  <https://orcid.org/0000-0002-2505-2152>

Tom R. Harcourt-Brown  <https://orcid.org/0000-0002-5980-472X>

Sergio A. Gomes  <https://orcid.org/0000-0002-9452-7262>

Mark Lowrie  <https://orcid.org/0000-0002-4993-589X>

Rodrigo Gutierrez-Quintana  <https://orcid.org/0000-0002-3570-2542>

#### REFERENCES

- The Kennel Club [Internet]. Press release: French Bulldogs overtake Labradors as UK's most popular dog breed [June 17, 2018]. <https://www.thekennelclub.org.uk/press-releases/2018/june/french-bulldogs-overtake-labradors-as-uks-most-popular-dog-breed/>.
- Mansour TA, Lucot K, Konopelski SE, et al. Whole genome variant association across 100 dogs identifies a frame shift mutation in DISHEVELLED 2 which contributes to Robinow-like syndrome in bulldogs and related screw tail dog breeds. *PLoS Genet.* 2018;14:e1007850.
- Bertram S, Ter Haar G, De Decker S. Congenital malformations of the lumbosacral vertebral column are common in neurologically normal French bulldogs, English bulldogs, and pugs, with breed-specific differences. *Vet Radiol Ultrasound.* 2019;60:400-408. <https://doi.org/10.1111/vru.12753>.
- Waters A. Brachycephalic tipping point: time to push the button? *Vet Rec.* 2017;180:288.
- Waters A. At last! Action to stop brachy dog ads. *Vet Rec.* 2017;181:635.
- O'Neill DG, Baral L, Church DB, et al. Demography and disorders of the French bulldog population under primary veterinary care in the UK in 2013. *Canine Genet Epidemiol.* 2018;5:3. <https://doi.org/10.1186/s40575-018-0057-9>.
- O'Neill DG, Darwent EC, Church DB, Brodbelt DC. Demography and health of pugs under primary veterinary care in England. *Canine Genet Epidemiol.* 2016;3:5. <https://doi.org/10.1186/s40575-016-0035-z>.
- Ryan R, Gutierrez-Quintana R, Ter Haar G, De Decker S. Prevalence of thoracic vertebral malformations in French bulldogs, pugs and English bulldogs with and without associated neurological deficits. *Vet J.* 2017;221:25-29.
- Westworth DR, Sturges BK. Congenital spinal malformations in small animals. *Vet Clin North Am Small Anim Pract.* 2010;40:951-981.
- Moissonnier P, Gossot P, Scotti S. Thoracic kyphosis associated with hemivertebra. *Vet Surg.* 2011;40:1029-1032.
- Gutierrez-Quintana R, Guevar J, Stalin C, Faller K, Yeaman C, Penderis J. A proposed radiographic classification scheme for congenital thoracic vertebral malformations in brachycephalic "screw-tailed" dog breeds. *Vet Radiol Ultrasound.* 2014;55:585-591.
- Guevar J, Penderis J, Faller K, Yeaman C, Stalin C, Gutierrez-Quintana R. Computer-assisted radiographic calculation of spinal curvature in brachycephalic "screw-tailed" dog breeds with congenital thoracic vertebral malformations: reliability and clinical evaluation. *PLoS One.* 2014;9:e106957.
- Schlensker E, Distl O. Heritability of hemivertebrae in the French bulldog using an animal threshold model. *Vet J.* 2016;207:188-189.
- Brocal J, De Decker S, José-López R, et al. Evaluation of radiography as a screening method for detection and characterisation of congenital vertebral malformations in dogs. *Vet Rec.* 2018;182:573.
- Rohdin C, Häggström J, Ljungvall I, et al. Presence of thoracic and lumbar vertebral malformations in pugs with and without chronic neurological deficits. *Vet J.* 2018;241:24-30.
- Dewey CW, Davies E, Bouma JL. Kyphosis and kyphoscoliosis associated with congenital malformations of the thoracic vertebral bodies in dogs. *Vet Clin North Am Small Anim Pract.* 2016;46:295-306.
- Faller K, Penderis J, Stalin C, Guevar J, Yeaman C, Gutierrez-Quintana R. The effect of kyphoscoliosis on intervertebral disc degeneration in dogs. *Vet J.* 2014;200:449-451.
- Inglez de Souza MCCM, Ryan R, Ter Haar G, et al. Evaluation of the influence of kyphosis and scoliosis on intervertebral disc extrusion in French bulldogs. *BMC Vet Res.* 2018;14:5.
- Wyatt S, Lafuente P, ter Haar G, et al. Temporal-spatial gait analysis by use of a portable walkway system in French bulldogs with and without vertebral kyphosis. *Vet J.* 2019;244:45-50.
- Wyatt S, Gonçalves R, Gutierrez-Quintana R, De Decker S. Results of non-surgical treatment for congenital vertebral body malformations: 13 dogs (2009-2016). *J Am Vet Med Assoc.* 2018;253:768-773.
- Aikawa T, Kanazono S, Yoshigae Y, et al. Vertebral stabilization using positively threaded profile pins and polymethylmethacrylate, with or without laminectomy, for spinal canal stenosis and vertebral instability caused by congenital thoracic vertebral anomalies. *Vet Surg.* 2007;36:432-441.
- Charalambous M, Jeffery ND, Smith PM, et al. Surgical treatment of dorsal hemivertebrae associated with kyphosis by spinal stabilisation with or without decompression. *Vet J.* 2014;202:267-273.
- Mathiesen CB, de la Puerta B, Groth AM, Rutherford S, Cappello R. Ventral stabilization of thoracic kyphosis through bilateral intercostal thoracotomies using SOP (string of pearls) plates contoured after a 3-dimensional print of the spine. *Vet Surg.* 2018;47:843-851.
- Ryan R, Gutierrez-Quintana R, ter Haar G, De Decker S. Relationship between breed, hemivertebra subtype, and kyphosis in apparently neurologically normal French bulldogs, English bulldogs, and pugs. *Am J Vet Res.* 2019;80:189-194.

25. De Decker S, Gielen IM, Duchateau L, et al. Morphometric dimensions of the caudal cervical vertebral column in clinically normal Doberman pinschers, English foxhounds and Doberman pinschers with clinical signs of disk-associated cervical spondylomyelopathy. *Vet J*. 2012;191:52-57.
26. Angevine PD, Deutsch H. Idiopathic scoliosis. *Neurosurgery*. 2008;63:86-93.
27. Bolker BM, Brooks ME, Clark CJ, et al. 2009. Generalized linear mixed models: a practical guide for ecology and evolution. *Trends Ecol Evol* 2009; 24:127-135.
28. Draper NR, Smith H. Selecting the “best” regression equation. *Applied Regression Analysis*. 3rd ed. Hoboken: Wiley; 1998:327-368.
29. Youden WJ. Index for rating diagnostic tests. *Cancer*. 1950;3:32-35.
30. Aikawa T, Shibata M, Asano M, et al. A comparison of thoracolumbar intervertebral disk extrusion in French bulldogs and dachshunds and association with vertebral anomalies. *Vet Surg*. 2014;202:267-273.
31. McMaster MJ, Singh H. Natural history of congenital kyphosis and kyphoscoliosis. A study of one hundred and twelve patients. *J Bone Joint Surg Am*. 1999;81:1367-1383.
32. The Finnish canine expert—The Finnish Kennel Club [Internet]. Anu Lappalainen. Perinnölliset selkämuutokset. Nikamaepämuodostumat. <https://www.kennelliitto.fi/kasvatus-ja-terveys/koiran-terveys/perinnolliset-sairaudet-ja-koiran-hyvinvointi/perinnolliset-selkamuutokset>. Accessed November 18, 2018.
33. Langensiepen S, Semler O, Sobottke R, et al. Measuring procedures to determine the Cobb angle in idiopathic scoliosis: a systematic review. *Eur Spine J*. 2013;22:2360-2371.
34. De Rycke LM, Crijns C, Chiers K, et al. Late-onset wedge-shaped thoracic vertebrae in a six-month-old pug. *Vet Rec Case Rep*. 2016;4:e000317. <https://doi.org/10.1136/vetreccr-2016-000317>.
35. Mauler DA, De Decker S, De Risio L, et al. Signalment, clinical presentation, and diagnostic findings in 122 dogs with spinal arachnoid diverticula. *J Vet Intern Med*. 2014;28:175-181.
36. Yaman O, Dalbayrak S. Kyphosis and review of the literature. *Turk Neurosurg*. 2014;24:455-465.

**How to cite this article:** De Decker S, Packer RMA, Cappello R, et al. Comparison of signalment and computed tomography findings in French Bulldogs, Pugs, and English Bulldogs with and without clinical signs associated with thoracic hemivertebra. *J Vet Intern Med*. 2019;1-9. <https://doi.org/10.1111/jvim.15556>