

van Twist, D. J.L., de Leeuw, P. W., Spiering, W., Rossi, G. P.,  
Dominiczak, A. F., Jennings, G. L.R., Barigou, M., Persu, A. and Kroon, A.  
A. (2019) Unifocal and multifocal fibromuscular dysplasia: two different  
disease entities in a single patient? *Hypertension*, 73(1), pp. 7-12.  
(doi: [10.1161/HYPERTENSIONAHA.118.12004](https://doi.org/10.1161/HYPERTENSIONAHA.118.12004)).

This is the author's final accepted version.

There may be differences between this version and the published version.  
You are advised to consult the publisher's version if you wish to cite from  
it.

<http://eprints.gla.ac.uk/176989/>

Deposited on: 26 June 2019

## **Unifocal and Multifocal FMD: Two different disease entities in a single patient?**

Daan J.L. van Twist<sup>1</sup>, Peter W. de Leeuw<sup>1,2</sup>, Wilko Spiering<sup>3</sup>, Gian Paolo Rossi<sup>4</sup>, Anna F. Dominiczak<sup>5</sup>, Garry L.R. Jennings<sup>6</sup>, Mohammed Barigou<sup>7</sup>, Alexandre Persu<sup>8,9</sup>, Abraham A. Kroon<sup>2</sup>

<sup>1</sup> Department of Internal Medicine, Zuyderland Medical Centre, Sittard/Heerlen, The Netherlands

<sup>2</sup> Department of Internal Medicine and Cardiovascular Research Institute Maastricht (CARIM); Maastricht University Medical Centre (MUMC+), Maastricht, The Netherlands

<sup>3</sup> Department of Vascular Medicine, University Medical Center Utrecht. Utrecht, The Netherlands

<sup>4</sup> Department of Medicine -DIMED, Hypertension Unit, University of Padova, Italy

<sup>5</sup> Institute of Cardiovascular and Medical Sciences, College of Medical, Veterinary and Life Sciences, University of Glasgow, UK

<sup>6</sup> Sydney Health Partners, Sydney Medical School, University of Sydney, NSW, Australia

<sup>7</sup> University Paris Descartes, AP-HP, Hypertension Unit, Hospital European Georges Pompidou, France

<sup>8</sup> Department of Cardiology, Cliniques Universitaires Saint-Luc, Université Catholique de Louvain, Brussels, Belgium

<sup>9</sup> Pole of Cardiovascular Research, Institut de Recherche Expérimentale et Clinique, Université Catholique de Louvain, Brussels, Belgium

*The following case was presented 10 June 2018 as part of the Clinical-Pathological conference chaired by Anna F. Dominiczak and Garry L.R. Jennings at the 28<sup>th</sup> European Meeting on Hypertension and Cardiovascular Protection in Barcelona, Spain. Daan J.L. van Twist and Abraham A. Kroon presented the case.*

## Case Introduction

Fibromuscular dysplasia (FMD) is a heterogeneous group of non-atherosclerotic, non-inflammatory vascular diseases that can be classified into two subtypes based on their angiographic appearance: the multifocal type, with its typical string-of-beads pattern, and the unifocal type, presenting as a single focal stenosis.<sup>1,2</sup> As these two FMD entities differ substantially with regard to clinical and histopathologic characteristics, it has been suggested that unifocal and multifocal FMD in fact represent two different vascular diseases.<sup>3</sup> Recently, however, we observed a patient in whom imaging studies suggest the co-existence of unifocal and multifocal FMD in a single patient.

## Patient

A smoking, 45-year-old, white woman was admitted to hospital because of progressive postprandial abdominal pain in the previous 3 weeks. Gastroscopy was normal, but CT-scan revealed a 80% stenosis of the celiac trunk and occlusion of the superior mesenteric artery (Figure 1). Balloon angioplasty and stenting of the celiac trunk resolved her complaints, although this procedure was complicated by a dissection of the brachial artery. As the CT-scan showed no signs of calcification or thrombosis in the affected arteries and additional tests revealed no heart rhythm, lipid, coagulation, or inflammatory disorders, the etiology of these vascular abnormalities remained unclear. Therefore, she was referred to our outpatient clinic for further analysis.

## Discussion: Initial Differential Diagnosis

**Prof. Grossman:** It may be a type of vasculitis and we need to see some laboratory evaluation of the possibility of vasculitis.

**Dr. van Twist:** Yes, I think that is an excellent suggestion. I will show you it in a minute, the CRP and all the inflammatory markers are completely normal. So, there were no signs of inflammation by the time of admission.

**Dr. van Twist:** Any other suggestions, except for vasculitis?

**Prof. Bursztyn:** I would like to ask whether this woman had a loss of weight preceding to the symptoms? Sometimes when there is loss of fat, an angulation of the celiac axis occurs, and this angulation may be a stenosis and cause abdominal angina. Was there a history of substantial weight loss preceding the symptoms?

**Dr. van Twist:** The post-prandial pain started only three weeks before the hospital admission, and then the weight was stable. Only the last week she lost 2 or 3 kg. The disease you are suggesting is the Wilkie syndrome, also called the superior mesenteric artery syndrome, and that results in compression of the duodenum by the superior mesenteric artery. It does not lead to a stenosis of the vessel itself. So, I don't think that's the case here.

**Dr. Spiering:** Were there any clues of atherosclerosis or a smoking history?

**Dr. van Twist:** She had a smoking history for a few years, and the CT of the abdomen revealed only two little calcification spots in the distal aorta, but not in the vessels that were affected.

**Prof. Rossi:** My question is on the same line. Did the patient have familial hypercholesterolemia or severe hyperhomocysteinemia, because the differential diagnosis here is between atherosclerosis and FMD.

**Dr. van Twist:** The lipid levels were completely normal, and the total serum homocysteine level as well. Her family history was not suggestive for familial atherosclerosis either. Therefore, with the lack of these risk factors, atherosclerosis was considered less likely.

**Prof. Rossi:** Well, to get abdominal angina, you need to have occlusion of two out of the three vessels, and one with stenosis. You didn't tell us about the inferior mesenteric artery. Please do.

**Dr. van Twist:** It was completely normal, completely open.

**Prof. Dominiczak:** So, I have a different question. We are at a hypertension meeting, and we haven't heard anything about blood pressure of this patient. Could we hear a little more about her blood pressure, please?

**Dr. van Twist:** When came in our outpatient clinic, we started with additional history taking.

### **Patient History**

Upon history taking, several remarkable details were noticed. First, her medical history included a hypertensive crisis at the age of 36 years with blood pressure up to 240 mmHg systolic. This started rather abruptly (her blood pressure was normal one year before) and was currently well controlled with 3 antihypertensive drugs. In addition, she reported episodes of pulsatile tinnitus, which could occur in one or in both ears. One year ago, she underwent coronary angiography because of exertional chest pain with ST-segment elevation during exercise testing. The coronary angiogram showed no significant stenosis, but tortuosity of the coronary arteries was observed.

**Dr. Jennings:** Was that tortuosity of the coronary arteries noted at the time?

**Dr. van Twist:** According to the the cardiologist's report it was a little strange aspect of the distal coronary arteries. They didn't use the term tortuosity, but he noticed that it was not normal.

To summarize, we have a patient with visceral artery abnormalities, a stenosis of the celiac trunk, occlusion of the superior mesenteric artery, and additional history taking revealed a rapid onset hypertension, pulsatile tinnitus, and coronary tortuosity. Again, the question for the audience, what is your differential diagnosis now and what would you do next?

**Dr. Ratanjee:** So, it looks like it's a disease that is affecting at multiple levels. I think you would either need a CT angiogram or an MRA of all of the blood vessels in the body, especially the medium-sized arteries.

**Dr. van Twist:** Excellent suggestion, I think.

**Dr. Barigou:** Given the young age of the patient with the fact that she had multiple vessel involvement and the rapid onset of hypertension, the grade 3 hypertension is really important, we should seek for every secondary cause of hypertension practically because there is some involvement. Take a look to her renal arteries, if there is the same involvement and considering the abnormalities that were seen in her coronary arteries, couldn't we seek for Kawasaki disease that could give some coronary arteries in the same time a systemic disorder but is very rare in some conditions. That's my proposition.

**Prof. Persu:** Considering the additional history taking, each finding separately is not specific, but when we look at all the findings it's extremely suggestive for a wide-spread FMD. You have the hypertension. The Americans have taught us that the presence of tinnitus, especially swooshing, as you mentioned, is quite suggestive of carotid FMD. Then, coronary tortuosity is found in patients with spontaneous coronary artery dissection, which is strongly linked with FMD. So, I would say the probability of FMD is very high now.

**Dr. van Twist:** I think that's an excellent comment.

### **Fibromuscular Dysplasia?**

Given the rapid onset hypertension, pulsatile tinnitus, and coronary tortuosity we suspected FMD as the underlying vascular disease causing the abnormalities in the visceral arteries, but presumably with renal artery involvement as well. Revision of the abdominal CT-scan indeed suggested a stenosis of the left renal artery. The right renal artery appeared to be normal. Some small calcifications were noted in the distal aorta, but not at the level of the renal arteries or celiac trunk. In order to establish the diagnosis of FMD, a catheter-based renal angiography was performed (Figure 2). This confirmed the presence of a solitary stenosis in the left renal artery, which was suggestive for unifocal FMD. However, in the right renal artery, a string-of-beads was observed, consistent with the diagnosis of multifocal FMD.

**Prof. Kroon:** So, does this change your diagnosis or does this change your ideas with respect to what the diagnosis should be?

**Dr. Spiering:** No, it does not. I think it's typical for FMD, but what is really striking is that on the right renal artery you see a string of beads and on the left you see unifocal stenosis.

**Prof. Kroon:** Yes, indeed. I completely agree. Should that cause us to rethink the diagnosis? We have never seen a picture of the string of beads in one artery and unifocal stenosis on the other artery. We have seen unifocal disease on both arteries or in several sites in one patient, but not this combination.

**Dr. Spiering:** Well, actually that was my question to you. I've never seen such a case.

**Prof. Persu:** First about the focal lesion, how can you rule out that this is not atherosclerotic lesion, which is quite possible here?

**Prof Kroon:** Well, that's indeed what is very difficult, but we've been looking in detail in this patient to see whether there is atherosclerosis and as we said before, there are no signs of atherosclerosis anywhere, only small calcifications in the distal aorta. We have no other abnormalities in the aorta, and you know that atherosclerotic renal artery stenosis is an aortic disease, and there are no signs of that.

**Prof. Persu:** The second point is that with Dr. Jean-Philippe Lengelé (GHDC/UCL), we recently described three sisters with renal artery FMD, two have clear multifocal FMD and one has a focal stenosis on one side and on the other side mild irregularities compatible with multifocal FMD.<sup>4</sup> So, I think the association is rare, but it does exist. Also, I am aware of at least one family from Paris in which one sib had multifocal FMD and the other unifocal FMD. It's quite different, because it's not the same patient, but still the fact that unifocal and multifocal FMD may occur in first-degree relatives suggests it can be the same disease.

**Prof. Kroon:** Thank you for your comment. I think I agree.

**Prof. Rossi:** Why the renal arteries were not looked at at the time when she was stented on the celiac trunk? At my institution when in a patient with hypertension, particularly if young, we usually do an examination of all of the arteries of the abdomen and also the epiaortic trunks, not only of the celiac trunk and the superior mesenteric artery.

**Prof. Kroon:** I completely agree with your comment, this should have been done the moment she was stented in the celiac trunk. However, this study was in another hospital, and at that time they didn't have the hint that this was FMD. Indeed, one should at least look into the renal arteries.

**Dr. Jennings:** Just in a similar way, did she have a renal bruit?

**Prof. Kroon:** She didn't have a bruit.

**Dr. Spiering:** Your center is an expert center on flow measurements of the renal arteries. Did you do these measurements in this patient?

**Prof. Kroon:** In this patient we didn't do the flow measurements and that's due to shortage of <sup>133</sup>Xenon (which is used for the flow measurements) at that time. Otherwise, of course, I would have shown you these data.

**Prof. Dominiczak:** Could I ask a naïve question? Clearly in clinical practice at this stage we would say this is FMD. It could be one or two types, but this is a young woman. We would proceed to angioplasty, because we want to treat this condition. So, does it matter all that much that one renal artery is slightly different than the other? The only worry would be that one is atherosclerotic and the other is FMD. But if you could with all logical clinical arguments exclude atherosclerosis, for me, you would just proceed with action.

**Prof. Kroon:** Well, you're completely right, but there may be a difference. If it's FMD, you only do the balloon dilatation, and if it's atherosclerosis you would prefer to put a stent on that left renal artery. So, there may be a difference. But, indeed, the discussion is a bit academic. So, our diagnosis.

## Diagnosis

We report a case of a patient with multiple vascular lesions that are suggestive of two different types of FMD in single patient: multifocal FMD in the right renal artery and unifocal FMD in the celiac trunk and left renal artery. Presumably, the occlusion of the superior mesenteric artery is also related to FMD, either as a result of spontaneous dissection or progression of a severe stenosis.

Since the co-occurrence of two FMD subtypes in one individual patient is rare, we considered alternative diagnoses. As there was no vascular tissue available for histological examination, the diagnosis had to be made on clinical information and imaging studies alone. However, in our opinion, there is not much doubt about the diagnosis of multifocal FMD, as the string-of-beads pattern that was observed in the right renal artery is very characteristic. Moreover, symptoms like pulsatile tinnitus and exertional chest pain (attributed to cervical and coronary tortuosity, respectively) are also often reported by patients with multifocal FMD.<sup>5,6</sup> The solitary lesions in the celiac trunk and left renal artery, however, may have a different etiology than unifocal FMD. Yet, we found no clues for inflammatory diseases or syndromic abnormalities such as neurofibromatosis or Ehlers-Danlos syndrome. The most plausible alternative explanation would be that these lesions are caused by concomitant atherosclerosis, which is not uncommon in patients with multifocal FMD. The presence of (subtle) atherosclerotic changes in the aorta and cigarette smoking as a risk factor may point towards that. However, the imaging studies did not reveal any calcifications in or near the severe stenoses in the celiac trunk, superior mesenteric

artery, or left renal artery. Although we cannot fully rule out that these lesions are all caused by non-calcified soft plaques, we would have expected at least some calcification in case of diffuse atherosclerosis that already progressed to multiple clinically relevant stenoses. Therefore, we consider it most likely that the lesions in the celiac trunk and left renal artery are caused by unifocal FMD.

This observation of co-existence of unifocal and multifocal FMD in a single patient was quite unexpected, as there are several reasons to assume that these two FMD subtypes are, in fact, two different diseases. First, and most importantly, the affected layer of the vessel wall differs between unifocal and multifocal FMD.<sup>1,2</sup> In multifocal FMD, the medial layer is affected, with alternating areas of thick and thin medial fibroplasia that result in the typical string-of-beads appearance (as observed in the right renal artery of our patient). In unifocal FMD, however, fibroplasia of the intimal or adventitial layer is present over a shorter segment, resulting in a focal, solitary stenosis. Furthermore, patients with unifocal FMD are generally younger (26 vs. 40 years), more often male (31% vs. 17%), and have higher blood pressure upon presentation (157/97 mmHg vs. 146/88 mmHg).<sup>7</sup> In addition, the pathophysiological mechanisms leading to hypertension appear to differ between these entities, with preserved renal perfusion and normal renin secretion in multifocal FMD, but a classical pattern of renovascular hypertension with reduced renal blood flow and increased renin secretion in unifocal FMD.<sup>8</sup> These differences in histological, angiographic, pathophysiological, and clinical characteristics do not point towards variations of a single disease, but rather towards two different diseases.<sup>3</sup> That is presumably the reason why the co-occurrence of these two FMD subtypes in one individual patient is rare: the probability of co-occurrence of two relatively rare vascular diseases in one single patient is, statistically speaking, extremely low. Although several review articles reported that patients with both unifocal and multifocal lesions exist,<sup>1,9</sup> these statements are (to the best of our knowledge) not supported by any original case descriptions in the literature. Histological studies have reported that two layers of the vascular wall can be affected in one single vessel segment,<sup>9,10</sup> but that is fundamentally different than multifocal FMD in one artery and unifocal FMD in another. The lack of such case descriptions in the literature illustrates the rarity of this combination and supports the concept of two different diseases. Nevertheless, this appears to be the case in our patient, perhaps the exception that proves the rule.

**Prof. Rossi:** I find this a very interesting academic discussion, but so far we have not enough solid data to solve this dilemma between one single disease or two disease. Unfortunately, as you pointed out, we do not have the option to examine these arteries histopathologically and molecularly since the introduction of renal artery angioplasty. Hence, going back to Professor Dominiczak's point, is this important to clarify if this is atherosclerosis or FMD? I had experience with quite a few patients with long-standing hypertension starting at the very early age and never screened for secondary forms, that developed atherosclerotic changes over time with vessel calcifications. In other words, these patients start with FMD and after 20 - 40 years, because of the raised blood pressure, the chronic activation of the renin-angiotensin-aldosterone system and also because of aging and exposure to other risk factors they also develop atherosclerotic lesions, with worsening hypertension which often becomes severe and resistant to drug treatment. I think if I may say this, that with physicians following the "polypill approach" and giving up on early screening for secondary hypertension, we will see many more of these cases in the future.

**Prof. Kroon:** Well, I completely agree with this comment. This is something we've seen already with a patient of 65 years old who presented with FMD and an atherosclerotic renal artery stenosis in one renal artery. So, it's a combination, and it's due to not diagnosing the FMD at early ages. But I think we have to decide now as to whether we should do something with this patient, and that may be a point of discussion. Are we going to do balloon angioplasty in this patient or not?

**Dr. Sharabi:** I think it is critical to perform balloon angioplasty. A few years ago, I think it was 2010, a study was published in *Hypertension* on the outcome of angioplasty in FMD,<sup>11</sup> and apparently age is a major factor because you want to cure patients with FMD. So, at a certain age the likelihood that she will be cured and not need medication is critical. So, at her age, if I remember well the graph that looked at the age and response to treatment in terms of long-term response, she is about like 30 to 40% chances that she will be cured from her blood pressure. So, we must decide whether it's worth the angioplasty. The other thing, again, this goes back to what is the etiology? If it is atherosclerosis, then the likelihood is even less. Therefore, I think that age and the duration of the patient's hypertensive disease are two important factors that will tell you whether or not it's worth going for balloon angioplasty.

**Prof. Persu:** I think I would go for pressure gradient measurements in this patient, because we're not completely sure the focal lesion is FMD, so how will it respond, and the typical string of beads on the other side looks relatively mild. Also, we have learned from Professor Olin that with the same string of beads aspect you can have gradients from zero to a very high gradient. I agree there are no specific studies on pressure gradient measurements in FMD, as we discussed already, but still from a pragmatic point of view, I would do it for this patient.

**Prof. Kroon:** Well, if one proceeds to pressure gradient measurements along the abnormal artery, the difficulty still remains in what one should take as the cutoff levels of the difference in blood pressure between the pre-stenotic and the post-stenotic arterial segment. Interestingly, we have only data from studies in subjects with atherosclerotic renal artery stenosis and not in FMD. So, what would be the cutoff to decide to go for intervention or not.

**Prof. Persu:** Admittedly, we have no evidence-based specific cutoff for FMD, but again, if the gradient is near to zero, which is, I think, is possible here, what would you do? Would you revascularize only the artery with the focal stenosis, and in this case would you put a stent or not? The question is difficult to answer.

### **Decision for Treatment**

As the trans-stenotic pressure gradient was relatively low (13 mmHg on the right side, 15 mmHg on the left), her blood pressure was well controlled, and kidney-size and renal function were normal, she was managed conservatively without renal artery intervention.

**Prof. Kroon:** We had some arguments for what we did. One argument is this curve (Figure 3).<sup>11</sup> We have a 45-year-old lady in which the pretest chance of curing her hypertension would be something between 30 and 40%. Then, we had a well-controlled blood pressure with three antihypertensive drugs. Her systolic blood pressure was below 140 mmHg. She had a normal kidney size, so no atrophic kidneys, especially on the left side. She had normal renal function with respect to eGFR. We did the transstenotic pressure gradient, and we measured on the right side a pressure gradient of 13 mmHg and on the left side a pressure gradient of 15 mmHg, which is somewhat less than 10% of a change. Although one can dispute this decision, we decided not to do a balloon angioplasty with this information. We decided to control her blood pressure level closely, and the moment there are significant changes in blood pressure level (without changes in medication) or changes in kidney function, we will review our current decision and may go for angioplasty at that time in this patient. But, of course, this is debatable, but that was our choice.

**Prof. Dominiczak:** So, could I ask you, what sort of follow-up? How carefully and frequently are you going to follow-up this patient, because of course lesions could progress. We've all seen, sometimes quite rapid, progression of renal artery stenosis, whatever the etiology. So, how frequently are you seeing this lady in your specialist clinic?

**Prof. Kroon:** We see her every three months, and we do our standard blood pressure measurements and once every six months we have a creatinine level in this patient and up until now everything has gone as we described here.

**Prof. Dominiczak:** Okay. So, any comments on this management?

**Dr. Jennings:** Just a question of terminology. Do you consider then by this decision that this lady has renal artery disease but does not have renovascular hypertension?

**Prof. Kroon:** You're completely right. She has renal artery abnormalities, but we haven't shown that she has renovascular hypertension.

**Prof. Rossi:** Can you tell me where exactly you put your catheter for the pressure measurement?

**Prof. Kroon:** Yes. We came to the furthest point where we saw abnormalities, there we measured our blood pressure and we measured our blood pressure somewhere here for the left renal artery. So, really post-stenotic and post string of beads.

**Prof. Rossi:** The reason of my question is because I see theoretical problems with this measurement on several grounds. When you introduced a catheter you are narrowing the vessel and creating a gradient. Moreover, with multifocal FMD it is like when you are watering your garden and you have a number of bends of the tube: at the

end of the hose you have no water because you have no pressure. In other words, we are facing here multiple lesions in series, which taken individually may not look very severe, but add up in causing low perfusion to the kidney. Hence, one way around this difficulty could be to measure the resistivity within the kidney in the different poles and if you have a decreased resistivity index, this can be indirect evidence for the hemodynamic relevance of the stenosis. I don't know if you agree with it, but this is what we rely on at my institution. The important point here, however, is that one should look more at the heterogeneity of the values of the resistivity index across the different thirds of the kidney (upper, mid and lower) than at its absolute value. In fact, we found this to be more accurate in predicting the hemodynamic relevance of the lesions, particularly when you have multiple renal arteries and FMD involving just one of them.

**Prof. Kroon:** Well, we looked into duplex-echography studies of the renal arteries in the past, and did a careful study some years ago in our hospital. We found, however, that our results were not valid. So, we stopped doing measurements of the resistivity index, predominantly because of the fact that it's very operator-dependent. So, we didn't do the assessment in this case. There are case reports showing that you can do this with echo and show an increase resistive index, but unfortunately not in our hands.

With respect to the catheter measuring pressure, the catheter should be as small as possible, otherwise it will wedge, and then you have, of course, no pressure at all. So, you can make your stenosis if you want to.

**Dr. Barigou:** You didn't show us the results of renin and aldosterone in this patient.

**Dr. van Twist:** No, we didn't do it in this specific patient. The reason was that she was on antihypertensive medication with triple therapy. So, we didn't do a blood sampling for renin and aldosterone.

**Dr. Barigou:** Even though it could be valuable to do it before interpreting only imaging studies and not hormonal studies.

**Dr. van Twist:** No, I would never advise to do a blood sampling under triple therapy. The results you get are very difficult to interpret. If you want to do it, you should stop all the antihypertensive drugs. Or bridge them with other antihypertensive drugs, such as alpha blockers or calcium antagonists that do not have interaction with the renin-angiotensin system.

**Dr. Barigou:** Those are the guidelines.

**Dr. van Twist:** But in this case, we didn't stop the medication before, we just did this angiography.

**Prof. Dominiczak:** Okay. I think a very interesting case, and if I can be a prophet, I think it will get worse. I think we will invite the team to come back to one of our clinical pathological conferences to give us feedback two, three years on. So, the invitation stands.

## Summary

In summary, we discussed a unique case of a patient in whom imaging studies suggest the co-existence of multifocal and unifocal FMD in a single patient. Further research is needed to determine whether multifocal and unifocal FMD are subtypes of the same disease, or, in fact, represent two different vascular diseases that occurred simultaneously in one patient. Balloon angioplasty to treat hypertension appears to be effective in a subset of patients with FMD, but whether its effect can be predicted by measurement of the trans-stenotic pressure gradient remains unclear.

## Acknowledgments

The authors are grateful to the following session audience members for contributing to the discussion: Ehud Grossman, Michael Bursztyn, Sharad Ratanjee, Yehonatan Sharabi.

## Disclosures

None

## Sources of Funding

None

## References

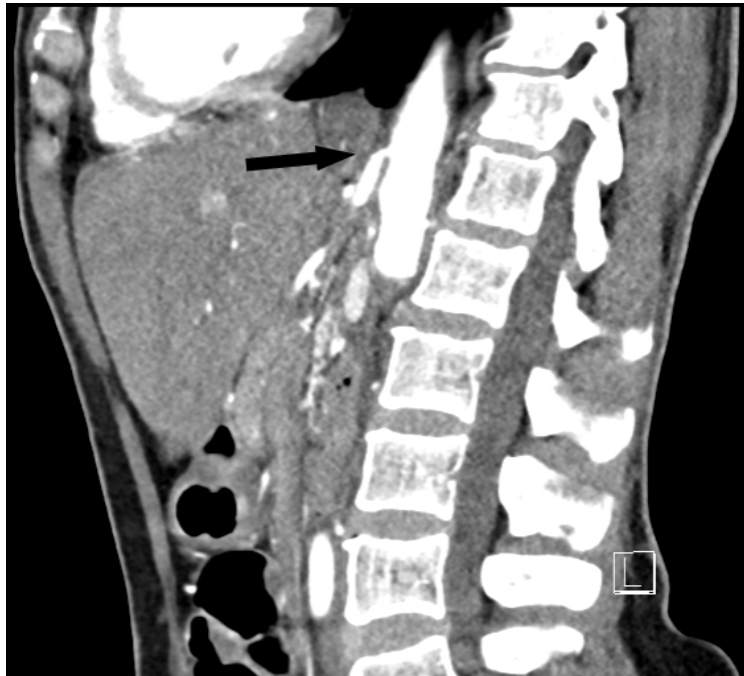1. Olin JW, Gornik HL, Bacharach JM, et al. Fibromuscular dysplasia: state of the science and critical unanswered questions: a scientific statement from the American Heart Association. *Circulation*. 2014;129:1048-1078.
2. Persu A, Van der Niepen P, Touze E, et al. Revisiting Fibromuscular Dysplasia: Rationale of the European Fibromuscular Dysplasia Initiative. *Hypertension*. 2016;68:832-839
3. Olin JW. Is fibromuscular dysplasia a single disease? *Circulation*. 2012;126:2925-2927.
4. Di Monaco S, Georges A, Lengelé JP, Vikkula M, Persu A. Genomics of fibromuscular dysplasia. *Int J Mol Sci* 2018;19:1526.
5. Olin JW, Froehlich J, Gu X, et al. The United States Registry for Fibromuscular Dysplasia: results in the first 447 patients. *Circulation*. 2012;125:3182-3190.
6. Van Twist DJ, de Leeuw PW, Kroon AA. Coronary tortuosity: a clue to the diagnosis of fibromuscular dysplasia? *Am J Cardiol* 2017;30(8):776-80.
7. Savard S, Steichen O, Azarine A, Azizi M, Jeunemaitre X, Plouin PF. Association between 2 angiographic subtypes of renal artery fibromuscular dysplasia and clinical characteristics. *Circulation*. 2012;126:3062-3069.
8. van Twist DJ, de Heer PW, Houben AJ, de Haan MW, de Leeuw PW, Kroon AA. Differences in renal hemodynamics and renin secretion between patients with unifocal and multifocal fibromuscular dysplasia.. *J Hypertension* 2018;36(8):1729-1735.
9. Plouin PF, Perdu J, La Batide-Alanore A, Boutouyrie P, Gimenez-Roqueplo AP, Jeunemaitre X. Fibromuscular dysplasia. *Orphanet J Rare Dis*. 2007;2:28.
10. Alimi Y, Mercier C, Pellissier JF, Piquet P, Tournigand P. Fibromuscular disease of the renal artery: a new histopathologic classification. *Ann Vasc Surg*. 1992;6:220-224

11. Trinquart L, Mounier-Vehier C, Sapoval M, Gagnon N, Plouin, PF. Efficacy of revascularization for renal artery stenosis caused by fibromuscular dysplasia: a systematic review and meta-analysis. *Hypertension* 2010;56(3):525-32.

## Figures

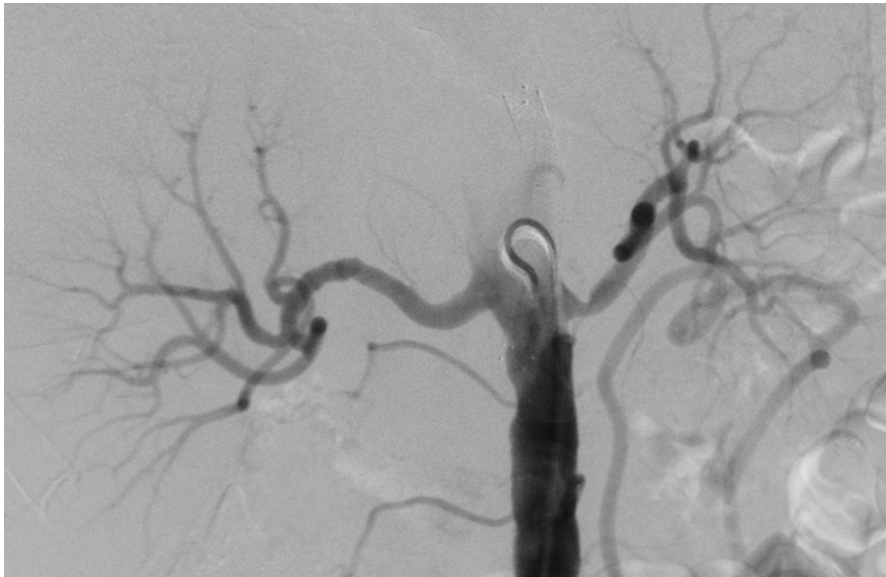## Figures

Figure 1:



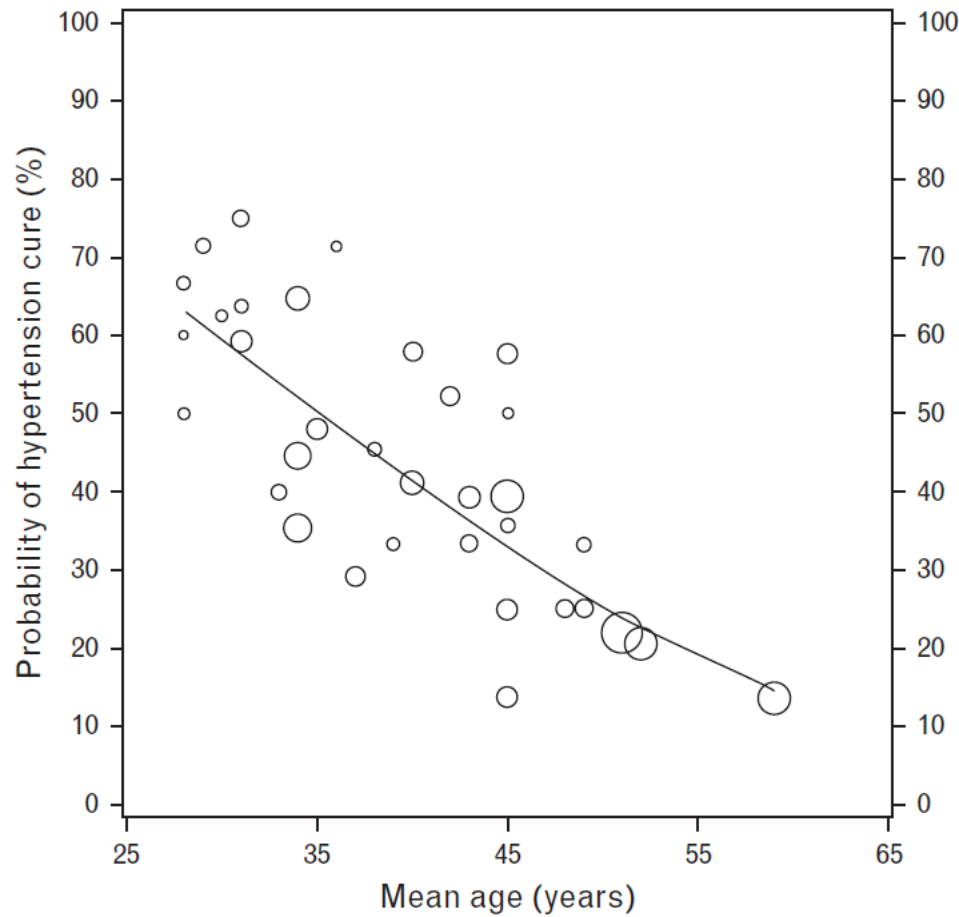
Contrast-enhanced computed tomography (CT) scan of the abdomen in the sagittal plane revealing a 70-80% stenosis of the celiac trunk (arrow).

Figure 2:



Digital subtraction angiography of the aorta with the catheter positioned at the kidney level. Note the string-of-beads pattern in the right renal artery, the solitary stenosis in the left renal artery, and the stent in the celiac trunk.

Figure 3:



Meta-regression analyses assessing the relationship between age and the hypertension cure rate after renal artery balloon angioplasty. Adapted from Trinquart L, Mounier-Vehier C, Sapoval M, Gagnon N, Plouin, PF. Efficacy of revascularization for renal artery stenosis caused by fibromuscular dysplasia: a systematic review and meta-analysis. *Hypertension* 2010;56(3):525-32.