ISSN: 2321-8169
2265 – 2276

A Novel Method of Anatomical Data Acquisition Using the Perceptron ScanWorks V5 Scanner

Running title: Anatomical data acquisition using the Perceptron ScanWorks V5 scanner

Elizabeth Welsh, Paul Anderson, and Paul Rea[1]*
[1] Laboratory of Human Anatomy, School of Life Sciences,
College of Medical, Veterinary and Life Sciences, University of Glasgow, G12 8QQ, UK
Paul.Rea@glasgow.ac.uk
Phone +44(0)141 330-4366

[2]Digital Design Studio, Glasgow School of Art,
The Hub, Pacific Quay, Glasgow, G51 1EA, UK
p.anderson@gsa.ac.uk
Phone: +44 (0)141 566-1478

Abstract--A drastic reduction in the time available for cadaveric dissection and anatomy teaching in medical and surgical education has increased the requirement to supplement learning with the use of virtual gross anatomy training tools. In light of this, a number of known studies have approached the task of sourcing anatomical data from cadaveric material for end us in creating 3D reconstructions of the human body by producing vast image libraries of anatomical cross sections. However, the processing involved in the conversion of cross sectional images to reconstructions in 3D elicits a number of problems in creating an accurate and adequately detailed end product, suitable for educational.

In this paperwe have employed a unique approach in a pilot study acquire anatomical data for end-use in 3D anatomical reconstruction by using topographical 3D laser scanning and high-resolution digital photography of all clinically relevant structures from the lower limb of a male cadaveric specimen.

As a result a comprehensive high-resolution dataset, comprising 3D laser scanned data and corresponding colour photography was obtained from all clinically relevant gross anatomical structures associated with the male lower limb. This unique dataset allows a very unique and novel way to capture anatomical data and saves on the laborious processing of image segmentation common to conventional image acquisition used clinically, like CT and MRI scans. From this, it provides a dataset which can then be used across a number of commercial products dependent on the end-users requirements for development of computer training packages in medical and surgical rehearsal.

Key Words--*Digital reconstruction; 3D Laser scanning; lower limb anatomy*

*****

Background

Medical visualization has exploded recently with a plethora of techniques to image the human body. CT and MRI scanning has been around since the 1970's [1-3], but advancements in these techniques have been plentiful, both static and dynamic, and incorporating radionuclides. Indeed, these types of imaging techniques have been incorporated into medical and anatomical training since the invention of them. Over recent years, there have been a number of changes to the medical curricula, now placing more emphasis on the sciences underpinning medicine, especially in the UK. This has led to an increasing demand from anatomical educators for tools of a virtual nature, with the increasing use of interactive multimedia equipment more common.

Initially cross sectional anatomy was developed for teaching and research, with the major advancements coming in the form of the Visible Human Project (VHP), the Chinese Visible Human (CVH) and the Korean Visible Human (KVH) [4-6]. The first of these, the VHP, remains the benchmark in anatomical data collection today. It involved freezing and transversely sectioning whole male and female cadavers into slices of 1mm and one- third of a millimetre thick slices respectively, obtaining a total of 1878 slices for the male, completed in 1994, and 5189 slice for the female in 1995. Prior to cryosectioning, the cadavers were imaged in serial transverse and coronal planes by CT and MRI in order to supplement the photographic library of cross sections with one of corresponding radiological images [5]. Though this study was revolutionary in the field of anatomy teaching and research at this time, many problems have since been identified with the Visible Human Dataset (VHD) and the methodology used to acquire it. Extremely low freezing temperatures caused distortion of the neural tissues and cryosectioning resulted in data loss and tissue streaking across slices; all factors which impact upon the usability of the data for 3D processing [7].

Whilst the advent of these datasets has proved invaluable in many areas of research and medical imaging, the digital processing involved in the conversion of cross sectional images into gross 3D anatomical reconstructions, of a sufficient quality for medical training, remains a technically complex problem [8,9]. The greatest challenge lies in the

ISSN: 2321-8169
2265 – 2276

process of image segmentation, which is an essential step in the reconstruction of 3D structures from cross sectional images. This process involves each cross sectional image being carefully delineated into its constituent structures before being re-aligned in sequence to create stacks of surface contours, each representing a different structure in its three-dimensional form. Given the complexity and the vast number of anatomical cross-sections within these datasets, combined with poor colour differentiation and distortion of frozen and sliced tissues, this process can be extremely time consuming and not always entirely successful in achieving the accuracy and detail required for use medical teaching [10-12]. Even when 3D reconstruction is possible, surface textures can often be lacking in colour and texture realistic value [13]. For these reasons, a fully comprehensive and coherent 3D anatomical library has yet to be produced from the benchmark VHD [14]. Given the pressing requirement to produce more adequate reconstructions of human anatomy for the purpose of medical education and surgical simulation, these problems must be overcome.

More recently, 3D scanning technologies (including that of white light and laser scanning) have been investigated as to their potential use in medicine, although already used in other fields. One limitation of using laser scanning is that it only captures the surface of the object being scanned [15]. However, it has been shown that if this is combined with actual cadaveric dissection, it can create a much more viable reconstruction of the anatomical area [16]. If the anatomical areas are laser scanned, and combined with high-resolution colour imaging capture, it negates the need for arduous and complex procedures to reconstruct the cross-sectional data, and all the problems that are typically encountered in doing so.

In this paper we present an established workflow model using state of the art digital laser scanning equipment, cadaveric dissection protocol and digital expertise to design and reconstruct an area of wide clinical importance – the lower limb. This research was a pilot study and was conducted as part of a joint successful partnership between one of the largest anatomy laboratories in Europe – the Laboratory of Human Anatomy (LHA), University of Glasgow, and the internationally acclaimed Digital Design Studio (DDS), Glasgow School of Art. It enhanced the relationship further between the anatomical facilities which has a very successful bequethal program, dissection and surgical skills laboratories and historical anatomical and pathological collections, with the digital facilities at DDS which boasts a multi-disciplinary team with art, science and technology experts all housed together.

The aim of this study therefore was to collect anatomical data from dissected cadaveric material for specific end-use in creating a sophisticated and educationally valuable 3D reconstruction using a completely unique approach to data acquisition. This approach was taken with the view of obtaining high-resolution 3D data directly from the exposed surfaces of relevant anatomical structures in the dissection laboratory, thus eliminating the need for image segmentation. It is expected that in turn, this would facilitate the creation of more adequately detailed and realistic end-reconstructions of this anatomical region in the future which can then feature in virtual interactive training packages in medical education and surgical rehearsal.

Timeliness of Project

Over many years there has been a successful partnership between the LHA and DDS. The DDS moved to purpose built premises within the Digital Media Quarter in Glasgow and now houses one of the world's largest virtual reality and motion capture laboratories. It combines great internationally recognised expertise in a research and teaching environment, coupled with major commercial projects. The LHA is now one of Europe's largest anatomical facilities with a major dissecting room, surgical training suite, histology laboratories, historical collections of Hunterian anatomical and pathological specimens of international importance, Museum of Anatomy and runs many undergraduate and postgraduate courses within it. The collaboration between these two units has resulted in a formidable force in creating accurate digital reconstructions from actual cadaveric donations.

Indeed, medical, dental and surgical curricula have changed significantly from what was felt as a "dumbed down" curricula[17,18] to one with more emphasis on the underpinning of anatomy [19]. Coupled with this has been an increasing demand from anatomical educators for novel teaching methodologies and tools to aid teaching using digital technologies and interactive multimedia [20-22]. This has resulted in many anatomical training packages appearing on the market made, in part, by the VHD. Some of these packages include the VisibleBody [23], 3D4Medical [24], Cyber Anatomy [25], and Primal Pictures [26] to name a few.

Recently, through a three year funded project, we successfully created a ground-breaking package in head and neck anatomy based on dissected cadaveric material [27] which was viewed as one of the most significant pieces of research to benefit the wider public today [28].The uniqueness in what we do is in combining actual cadaveric dissection with image capture, laser scanning and digital reconstruction. All the other packages are based on the

ISSN: 2321-8169
2265 – 2276

idealistic impression of what the anatomy should be, whereas here, it is based on the real human data collected in the human anatomy laboratory. Although it is only gathered from a single donor at any one time, it has the potential to be added to by undertaking a series of these dissections on different donors followed by laser scanning, as well as the enormous potential to incorporate pathologies onto the "normal" anatomy which has been dissected and imaged. Therefore, with the increasing demand from anatomical educators for novel training packages, coupled with modern technologies, we piloted a study into laser scanning, high-resolution digital photography and digital reconstruction of all of the lower limb anatomy. This is to help in the construction of the digital human using novel technologies and approaches in reconstruction from cadaveric material without the demands of image segmentation from other scanning methodologies.

Data Collection

First, a cadaver had to be selected which would undergo dissection of all lower limb anatomy (nerves, vasculature, musculature and skeletal elements). The donor used was a 68-year old male selected from the regular stock in the LHA, School of Life Sciences, College of Medical, Veterinary and Life Sciences at the University of Glasgow. No obvious pre-existing lower limb anatomy was present and the cadaver was embalmed with a formalin-based solution, as per the normal LHA embalming protocol. All procedures were carried out under the auspices of the Anatomy Act 1984 [29] and the Human Tissue (Scotland) Act 2006, part 5 [30] and coordinated and managed by one of the co-authors (PR), the government's Licensed Teacher of Anatomy. Dissection instrumentation was standard for conventional soft tissue dissection; scalpel handles (size 4), and blades (size 24, 11), fine and blunt forceps, small scissors, dissection probes and standard formalin wetting solution. In addition to this, data acquisition was undertaken by using the Perceptron ScanWorks V5 3D laser scanner [31] and Cimcore Infinite 2.0 (Seven Axis Portable Co-ordinate Measuring Machine Arm (PCMM), Panasoni DMC T27 Lumix digital camera (12 x optical zoom, 10.1 megapixels) andportable laptop PC. The laser scanning was supported by PolyWorks V12, a 3D mesh processing software capable of aligning the partial scans and generating a mesh surface [32].

Cadaveric Dissection

Prior to the dissection, all clinically relevant anatomical structures associated with the male lower limb were listed and placed in a timetabled dissection agenda consisting of 9 'Blocks' as detailed in Table 1. Within each Block, the dissection agenda was broken down further into 'Key Stages' in order to ensure that all clinically relevant structures were exposed in a suitable step-by-step fashion for subsequent data acquisition. After completion of each Key Stage, i.e. after all clinically relevant anatomical structures listed for that stage had been adequately exposed, an episode of data acquisition could proceed via the methods detailed below. An example of a breakdown of the Key Stages for a selected Bock (Block C) is provided in Table 2.

Block of Dissection	Region of Lower Limb
A	Inguinal canal
B	External genitalia
C	Anterior and medial compartments of thigh
D	Anterior and lateral compartments of leg and dorsum of foot
E	Gluteal region and posterior compartment of thigh
F	Posterior compartment of leg
G	Sole of foot
H	Articulations
I	Bones

Table 1: Main Blocks of the dissection agenda indicating the order in which the regions of the male lower limb and associated regions were to be dissected.

ISSN: 2321-8169
2265 – 2276

Key Stages for Block C (Anterior and medial compartments of the thigh)	Relevant structures to be exposed by dissection
(i)	Superficial fascia
(ii)	Superficial veins (great saphenous vein and tributaries) and superficial nerves (lateral cutaneous nerve of the thigh)
(iii)	Rectus femoris, sartorius, vastus lateralis, vastus intermedius, gracilis, pectineus, tensor fascia latae, iliotibial tract, contents of femoral triangle
(iv)	Roof of adductor canal, and vastus intermedius
(v)	Adductor longus, contents of adductor canal.
(vi)	Adductor brevis, anterior division of obturator nerve, shaft of femur, adductor hiatus
(vii)	Adductor magnus and posterior division of obturator nerve
(viii)	Obturator externus

Table 2: Example of breakdown of a single Dissection Block (Block C: Anterior and medial compartments of the thigh) into Key Stages, indicating the relevant structures to be exposed at each for subsequent data acquisition.

The cadaver was placed on a mobile dissection table for the duration of the study to allow its position to be adjusted for subsequent data acquisition. The dissection area was restricted to the left lower limb region, the left half of the external genitalia (with the exception of the whole penis shaft) and the left inferior half of the lower abdominal wall limited by an upper skin incision spanning from the umbilicus to the mid lumbar region overlying L4 (Figure1). For Blocks A- D the cadaver was maintained in a supine position and from Block E onwards the specimen was turned into a prone position to allow access to the posterior regions. The exposed tissues were sprayed intermittently with standard formalin wetting solution and a polyethene sheet was used to cover the specimen when dissection was not in progress. The specimen was not sprayed in the twenty-four hour period prior to data acquisition to avoid the presence of excessive moisture interfering with tissue imaging. An episode of anatomical data acquisition was performed following each Key Stage of the dissection in two subsequent steps; 3D laser scanning to acquire surface profiles of the relevant dissected structures in the form of cloud point data and; digital photography to acquire a corresponding database of colour and texture information from the tissues.

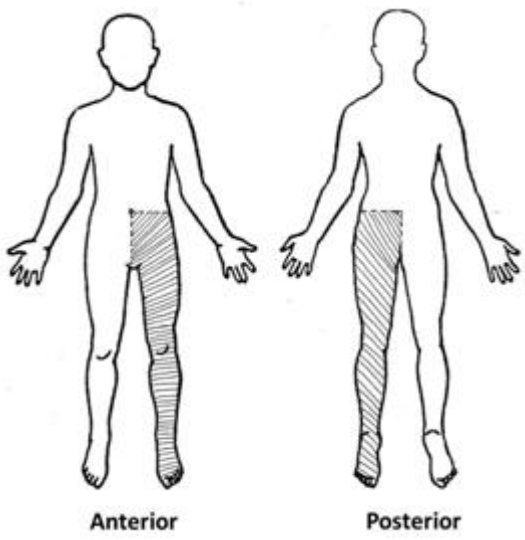

Figure 1. The boundaries of the dissected body region incorporating all regions of the left lower limb, inguinal canal and external genitalia.

3D laser scanning

Set up and handling

ISSN: 2321-8169
2265 – 2276

A Perceptron ScanWorks V5 Scanning probe, attached to the Cimcore Infinite 2.0 (seven axis) CMM (PCMM) arm was set up in accordance with the manufacturer instruction guidelines in conjunction with compatible computer scanning software. All handling of the scanning equipment, including set up, calibration, cadaveric scanning and subsequent data management was performed by one of the co-authors (PA). Data acquisition was performed in the LHA within a designated laboratory space with concrete flooring to minimise the risk of vibration interference and the scanning equipment was stored at constant room temperature for the duration of the study.

Prior to each episode of data acquisition, field calibration of the sensor within the scanner head was performed using positional feedback from PCMM to align the sensor into a common co-ordinate frame with the computing software. The hard probe then was calibrated to collect cloud point (surface profile data) at a point-to-point resolution suitable for the intricacy of the relevant structures (up to 12µm).

The cadaver was placed in a position to facilitate suitable access by the scanner head connected to the PCMM. The articulated measuring arm of the PCMM could be rotated 360°around a stationary tripod stand on the laboratory floor. Where relevant anatomical structures were situated on the medial aspect of the lower limb, the hip joint was abducted to facilitate access to these structures by the scanner head. Once this position was established it was ensured that the specimen and the PCMM tripod was not moved until laser scanning was complete.

Scanning procedure

Scanning of the dissected anatomical structures was performed in a proximal to distal direction, perpendicularly to the horizontal axis of the laser stripe emitted by the scanner head onto the cadaveric surfaces. To maximise the efficiency of each scan, the operator was guided by a number of cues which indicated the optimal scanning distance from the face of the scanner hard probe including a visual representation of the hard probes cone-shaped field of view, and a changeable audible tone produced by the scanning software.

For each Key Stage of the dissection, multiple scans were performed from various angles and the cloud point data from each scan was automatically aligned into a common co-ordinate frame by the computer software, using feedback from the PCMM. This was repeated until sufficient surface profiles of all relevant structures exposed by that stage of the dissection had been obtained. The data obtained was evaluated after each scan by carefully scrutinising a visual output of the data presented on the portable laptop PC monitor. This visual output was presented in the form of a 3D grey-scale polygon mesh reconstruction of the scanned area, derived directly from the cloud point data obtained from exposed cadaveric surfaces. This image was carefully scrutinized after each scan by both anatomy and digital modelling experts and could be magnified or rotated in real time by the operator to facilitate a thorough assessment of data acquisition in relation to the relevant anatomical structures. Black areas on this image indicated areas of data deficiency, and where associated with relevant structures, a requirement for further scanning of that area. Further scanning of data sufficient areas was avoided to prevent the collection of replicated or redundant data. Once a sufficient surface profile for all relevant structures had been obtained, scanning was stopped and the data saved on an external hard drive for subsequent use.Following each episode of scanning, the dissection was photographed from various angles with the Panasonic DMC T27 Lumix digital camera to obtain surface colour and texture information from all relevant structures imaged during the scan. All photography was performed in constant ambient light levels with the use of a flash to optimise colour intensity.

Results of dissection and scanning

The dissection component of this study facilitated a clear demonstration and adequate surface exposure of all relevant gross anatomical structures listed in the initial dissection agenda for subsequent data acquisition from the male lower limb. Upon dissection, the specimen presented almost completely normal anatomy with the exception of a small amount of arthritic change on the articulating cartilage of the knee joint, including the patella, proximal tibia and the distal end of the femur. There was no significant loss or deformation of any relevant anatomical structure as a result of the dissection process.

Data acquisition

Laser scanning facilitated acquisition of high-resolution surface profiles in the form of cloud point data from all anatomical structures listed in the initial dissection agenda, at point-to-point resolutions up to 12µm. A corresponding library of colour digital photography for all relevant structures was also obtained from each Key Stage of the dissection. Figure 2 illustrates scan data obtained following the completion of a key stage of dissection in Block A (inguinal canal). It clearly demonstrates a clear, high-resolution surface profile of the anterior abdominal wall and proximal thigh structures in the form of a 3D polygon mesh derived from the cloud point data.

Figures 3-5provide examples of the scan data with corresponding digital photography from selected key stages

ISSN: 2321-8169
2265 – 2276

of the dissection, including those from; Block D (Figure 3); Block E (Figure 4), and Block G (Figure 5). In each example the relevant anatomical structures, all of which were listed on the initial dissection agenda for that Key Stage, have been indicated using a simple numbering system. Black areas on the grey-scale scan data represent areas of data deficiency; however these are not associated with the relevant anatomical structures highlighted in each example.

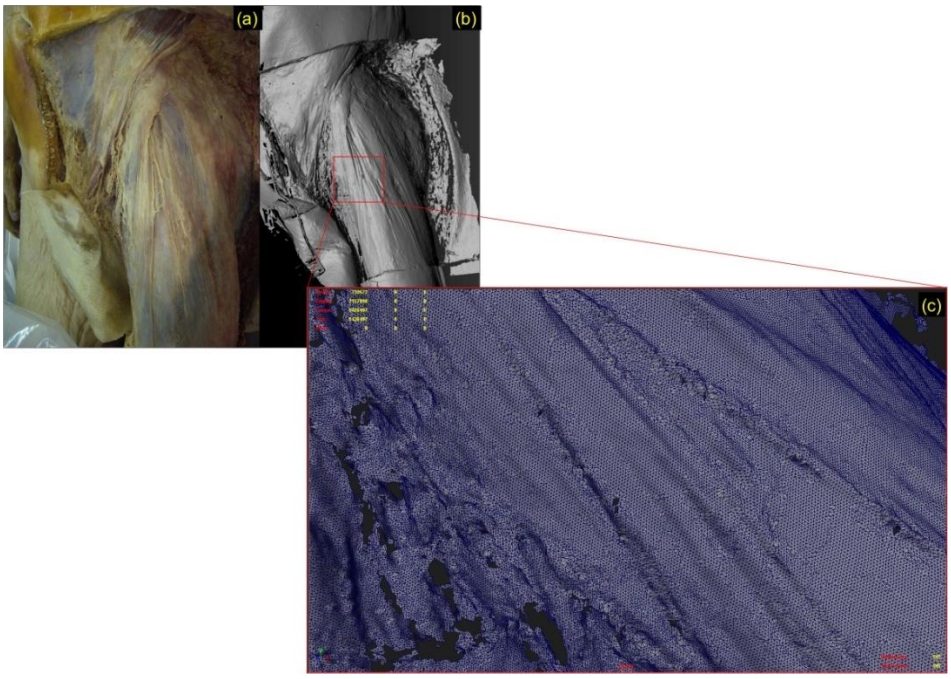

Figure 2. Scan data obtained following completion of a Key Stage (ii) of dissection Block A (the inguinal canal) (a) Digital photograph of key structures being demonstrated by key stage including external oblique aponeurosis, superficial inguinal ring and fascia lata of proximal thigh (b) Visual output of scan data which could be viewed on computer monitor during and after scanning was complete (c) Magnification of scan data illustrating manner in which point cloud data is meshed to create high resolution surface profile of relevant anatomical structures.

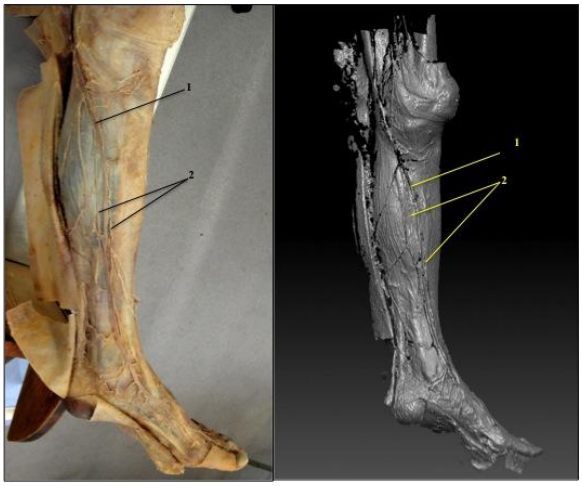

Figure 3. Scan data and corresponding colour photography obtained from Dissection Block D, Anterior and lateral compartments of leg and dorsum of foot (Key Stage (ii)). Structures of relevance at this Key Stage included superficial neurovascualture: (1) great saphenous vein; (2) saphenous nerves.

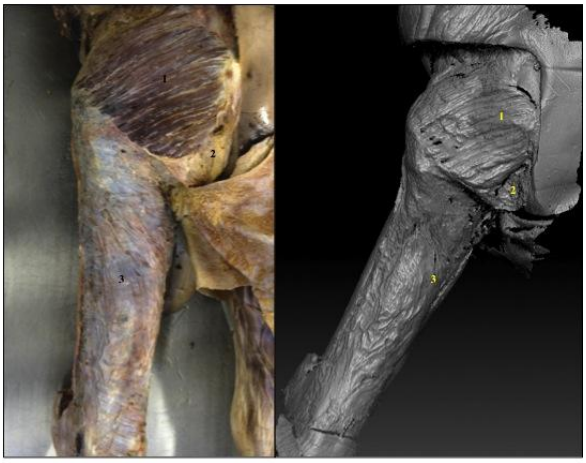

Figure 4. Scan data and corresponding digital photography obtained from Dissection Block E, Gluteal region and posterior compartment of thigh (Key stage (ii)). Structures of relevance at this key Stage included superficial musculature of gluteal region and deep fascia of the posterior thigh. (1) gluteusmaximus; (2) ischiorectal fossa; (3) fascia lata.

ISSN: 2321-8169
2265 – 2276

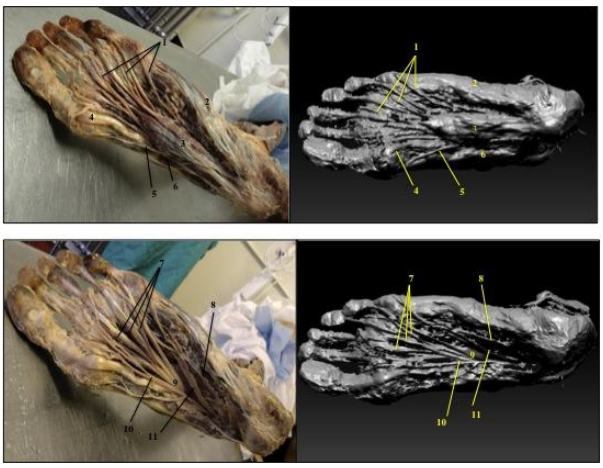

Figure 5. Scan data and corresponding digital photography obtained from Dissection Block G, Sole of the foot (key Stages (ii) and (iii)). The structures of relevance at Key Stage (ii) (above), were those associated with the first layer of the sole of the foot. Those of relevance at Key Stage (iii) (below), were associated with the second layer of the sole of the foot. (1) digital nerves; (2) abductor digitiminimi; (3) flexor digitorumlongus (tendon); (4) flexor hallucislongus (tendon); (5) medial plantar nerve; (6) abductor hallucis; (7) lumbricals; (8) lateral plantar artery; (9) flexor digitorumlongus; (10) medial plantar nerve; (11) lateral plantar nerve

Data processing

As each anatomical structure was captured with the Perceptron ScanWorks V5 3D laser scanner, it was also captured with high-resolution colour image capture using PolyWorks V12. This therefore meant a large data bank was collected of ALL lower limb structures and reconstructed in this software. It allowed a novel approach to visualising these anatomical structures and as it was captured in stages, the end user would then be able to select either a global or narrow field to examine the topographical scanned data in detail. With the capture of high-resolution colour imagery, the data can then be manipulated in a number of ways using a variety of products on the market e.g. Zbrush, Photoshop and Autodesk Maya. The purpose of this pilot study was, in the first instance, to collect the raw data and compose the highly accurate 3D model of the anatomy of the lower limb.

Verification of anatomical structures

Throughout the process of dissection and data capture, it was essential to maintain accuracy of the anatomical structures and reconstruction using the software. Members of a clinical advisory board, who, in collaboration with other projects, ensured clinical relevance to the detail gathered and reconstructed and provided external validation. This group contained members from medical, surgical and life science experts. Indeed, specific to the study in hand, it was also validated by an experienced senior clinical anatomist and government Licensed Teacher of Anatomy, who was also one of the co-authors of this work (PR).

Discussion

This study shows a novel approach to anatomical data acquisition; involving gross cadaveric dissection, high-resolution laser scanning and colour digital photography which can be used to create an extremely useful dataset for subsequent digital modelling and reconstruction of human anatomy.

The Perceptron ScanWorks®V5 scanner was selected for this study based on its advanced technology in the field of laser imaging. It has been approved by government and military engineers as a means of Reverse Engineering Inspection of mechanical parts and is quoted as being class leading in its field [33,34]. For this reason it is already a popular choice of digital imaging modality in many disciplines, such as mechanical engineering, aeronautical engineering, animation and many more [33, 35]. The V5 scanner can be calibrated to perform data acquisition of a point-to-point resolution of up to 12 µm and is unaffected by moderate levels of light reflection from moist surfaces making it an ideal choice for imaging intricate anatomical structures from human tissue. Additionally, according to the published Knowledge Base Document on 'V-Series Accuracy, Standards and Traceability', Perceptron guarantee rigorous factory rectification and equipment testing, offering assurance that the scanner used will perform data acquisition with a high measurement accuracy (24µm 2σ throughout its view field). For the 3D data acquisition component of this study, this scanner therefore achieved accurate surface profiling, all structures considered relevant to medical anatomy education for the lower limb, including those associated with the skin, muscles, nerves and even lymph nodes, as listed in the initial dissection agenda. The range of examples given in Figure's 3-5 indicate the ability of the scanner to acquire data from structures with larger surface areas such as layer of deep fascia (Figure 4), to more intricate structures including nerves, vasculature and fine musculature, such as that found in the sole of the foot (Figure 5). The ScanWorks V5 Scanner can also integrate data collection in real-time with a number of industry recognized modelling softwares, such as PolyWorks, Geomagic, Rapidform XO etc., giving the operator flexibility to choose from an array of sophisticated interfaces to use in conjunction with the scanning hardware.

As well as the sophisticated imaging technology having an important role to play in the usefulness of the dataset obtained in this study, the quality of this data was also largely dependent on the suitability of the specimen used and the adequacy of the dissection itself. The specimen used

ISSN: 2321-8169
2265 – 2276

was suitable for demonstrating normal lower limb anatomy, and featured no obvious abnormalities with the exception of a small amount of arthritic change on the articulating surfaces of the knee joint. All structures listed in the original dissection agenda were dissected clearly to maximise surface exposure of the relevant anatomical structures in order to facilitate optimal surface profiling in 3D by the laser scanner. In addition to the scan data, the high-resolution colour photography will provide digital modellers with a corresponding dataset of colour and texture which will be used in conjunction with the scan data to produce an end reconstruction which is realistic, anatomically accurate and sufficiently detailed for the male lower limb.

Previous studies, such as the VHP, KVH and CVH have lead the way in sourcing anatomical data from cadaveric material, however have employed very different approaches in their methods of doing so. The VHP initially set the benchmark for this type of research in the 1990's. The VHP approached this task by freezing and cross-sectioning male and female cadavers into two-dimensional slices of 1 mm and 1/3 mm slices respectively, obtaining a total of 1878 slices for the male, completed in 1994, and 5189 slices for the female in 1995. Prior to cryosectioning, the cadavers were imaged by CT and MRI scanning in both transverse and coronal planes, and these radiographic images were then coupled with colour photographs of the corresponding cryosectioned slices to produce the most comprehensive digitised anatomical dataset of its kind [5]. Since its completion in 1995, many educational and commercial projects have attempted to use the Virtual Human Data (VHD) to create three-dimensional reconstructions for anatomical training purposes with varying levels of success [10, 36, 37]. Despite the important role the VHP has played in the field of medical visualisation research and education, a number of problems have been identified with the usability of this dataset for reconstructing anatomy in 3D as a direct result of the methodology used to acquire it. One of the major disadvantages with the VHD is that uncontrolled loss of important anatomical data came about as a result of the physical milling process. The male and female cadavers were sectioned first into four separate regions prior to finer cryosectioning with a relatively thick "backsaw", resulting in three horizontal junctions of 1.5mm cross-sectional data loss across the thorax, mid-thigh, and upper leg regions [5, 6].Small fragments of data were then lostfrom delicate or brittle structures such as teeth, nasal conchae and articulating cartilages, and tendons were also streaked across many of the anatomical slices. The necessity to freeze the specimens at excessively low temperatures prior to cryosectioning also caused distortion of the neural tissue, blood vessel collapse and poor colour differentiation between certain adjacent tissues [6], all of these factors having implications for the use of this data as a source for reconstructing the affected structures in 3D [38]. Similar projects, such as the KVH and CVH, have since attempted to improve on the VHP methodology of data collection, and to produce datasets that are more typically representative of the East Asian population, by sectioning at smaller intervals and photographing at higher resolutions [4, 6]. The CVH project, launched in 2001, claims to have produced the most comprehensive anatomical dataset to date, producing photographic images of 2518 slices for the CVH male, and 3640 slices for the CVH female at higher resolutions than both previous studies [4, 6].

Whilst these studies have proved invaluable in the field of medical imaging research and in various aspects of medical education, the conventional method of freezing and sectioning cadavers still elicits a number of problems in the usability of this data for anatomical reconstruction in 3D. The problems here lie in the necessity to perform the process of image segmentation which involves the meticulous and time-consuming task of delineating the numerous cross sectional images into their constituent structures [10, 11, 36]. This step must be performed successfully for each relevant body slice before the segmented cross sections can then be realigned in sequence to reconstruct the constituent anatomical structures from stacks of adjacent surface contours [9, 39]. Due to the complexity of the anatomical cross sections, this process can only be performed manually or using semi-automated computer algorithms, which involve the careful sorting of individual image pixels into constituent regions by intensity thresh-holding or colour differentiation [8, 9]. The quality of the reconstruction produced is therefore highly dependent on successful image segmentation, which in turn is determined by the quality of the cross-sectional data in terms of the slice intervals, image resolution, and the precision of slice re-alignment [7]. With this approach to collecting anatomical data from cadavers, poor tissue colour differentiation between tendons and surrounding fatty tissue, the collapse of small blood vessels, and the streaking of structures across body slices results from the freezing and milling of the tissues, making structure delineation in some cases an extremely difficult task [4,6,10,13,39]. This creates a significant problem for deriving accurate and sufficiently detailed anatomical reconstructions for use in medical education from cross- sectional data. This is especially relevant in the reconstruction of musculoskeletal (and other soft tissue) elements, perhaps explaining why so few useful musculoskeletal computer-training applications have been developed from the aforementioned datasets [39]. Deep fascial layers have also proved difficult to reconstruct from anatomical cross-sections due to their relative thickness and

ISSN: 2321-8169
2265 – 2276

previous attempts to do this have depended upon successful delineation of associated musculature [13].

It is for the reasons discussed that image segmentation of anatomical cross sections cannot be done using automated algorithms and only by manual techniques. As well as being time consuming and subject to human error, even manual techniques are not effective for certain types of tissue reconstruction from image datasets of lower resolutions [8,9,10,12,13]. A semi-automated computer algorithm was successfully developed for segmenting the VHD by researchers at the University of Columbia but the authors predict that fully automated segmentation techniques are unlikely to ever achieve the level of precision required for the development of high standard anatomical teaching applications [8]. Due to these problems, a complete and coherent three-dimensional anatomical image library is yet to be produced from the benchmark VH dataset since its completion fifteen years ago, rendering the initial vision of this project as yet, unfulfilled [10].

Advantages of methodology

The approach used to source anatomical data from cadaveric material in this study offers a number of advantages over the conventional methods when concerned with the creation of virtual reconstructions in 3D for education. By using high-resolution laser scanning technology to obtain surface profiles from anatomical structures exposed upon cadaveric dissection, accurate 3D data can be obtained directly from the cadaveric source. This will therefore eliminate the necessity to conduct complex image segmentation on a vast library of cross sectional images prior to reconstruction of the relevant anatomy in 3D.

The high-end laser scanning technology used in this study is also capable of data collection at extremely high point to point resolutions (up to 12μm) facilitating accurate surface profiling of fine neurovasculature and lymph nodes, which cannot usually be reconstructed directly from cross sectional images.

Unlike previous studies, where important anatomical data has been lost during the harsh milling process or where tissues have streaked across the photographed slices, gross cadaveric dissection can be done in a controlled manner in order to demonstrate only clinically relevant structures clearly for subsequent data acquisition. If performed by an experienced prosector, this should result in no uncontrolled loss of important cadaveric data. Also slice misalignment, a problem which has been encountered in previous studies, is not a risk factor with scan data. Sets of cloud point data from individual scans are aligned by highly sophisticated automated computer software using digital feedback from the PCMM arm; used in conjunction with the laser scanner head. The Cimcore Infinite 2.0 (Seven axis) PCMM Arm used in this study is also issued with assured factory rectification and guaranteed performance accuracy assurance in the fidelity of this process.

Future developments

Before considering the use of this approach to cadaveric data acquisition for the purposes of anatomy education in the future, there are a number of factors which should be carefully considered.

Though embalming was necessary for the preservation of cadaveric tissues throughout the duration of this study, formalin causes alterations to the normal colour and texture properties of human tissue. This should be considered during post-processing of the data acquired and addressed by appropriate remodelling techniques under the direction of a highly skilled team of both anatomy and digital design experts. High-resolution colour photography collected from living or un-embalmed human tissues could be obtained with a view to using this as an additional reference at a later stage of digital modelling.

In using this approach, as with conventional cross-sectional approaches, care should be taken when selecting a suitable cadaver from which to acquire anatomical data. The dissection process must be carefully planned and every effort made not to modify or damage structures of importance. This can sometimes be difficult to achieve, especially when dissecting the finer neurovasculature. The specimen used in this study presented almost completely normal anatomy upon dissection, however there was a small amount of arthritic change on the articulating surfaces of the knee joint. This will be remodelled at a later stage of post-processing to fulfil the remit of creating an accurate reconstruction of normal lower limb anatomy, however this indicates the potential for this methodology in acquiring accurate data from sources presenting pathological anatomy in the future.

Conclusion and future work

Given the success of the methods used in this study for acquiring a comprehensive dataset from a cadaveric dissection of the male lower limb for end use in 3D anatomical reconstruction, this methodology could now be used to obtain data from other clinically relevant regions of the body. The male lower limb was specifically selected for this pilot for a number of reasons, including; its relative ease of access via simple soft tissue dissection techniques; its close association with the inguinal canal; its relevance to modern medical and surgical training; and the notable lack

ISSN: 2321-8169
2265 – 2276

of adequate virtual musculoskeletal training applications which are currently available to anatomy students.

Following on from the acquisition of the unique dataset for lower limb acquired in this study, thorough processing and digital remodelling of this data can then be used to develop advanced virtual training packages to supplement teaching in lower limb anatomy and surgical rehearsal, such as inguinal hernia repair. By using the scan data in conjunction with the corresponding colour photography, texture mapping of the 3D data can then take place in a variety of platforms dependent on the end-users requirements, like Blocks A-C developed in the prototype as shown in Figure 6.

Whilst the results of this study indicate a promising future for 3D virtual anatomy in medical and surgical education, it should also not go without mention that cross-sectional datasets remain an invaluable resource in many fields of teaching and medical imaging research [40-42]. This study shows however, that there is scope for improving the methods of acquiring anatomical data from precious cadaveric sources for the purpose of creating 3D reconstructions for education.

Acknowledgements

The Royal College of Physicians and Surgeons of Glasgow funded this project.

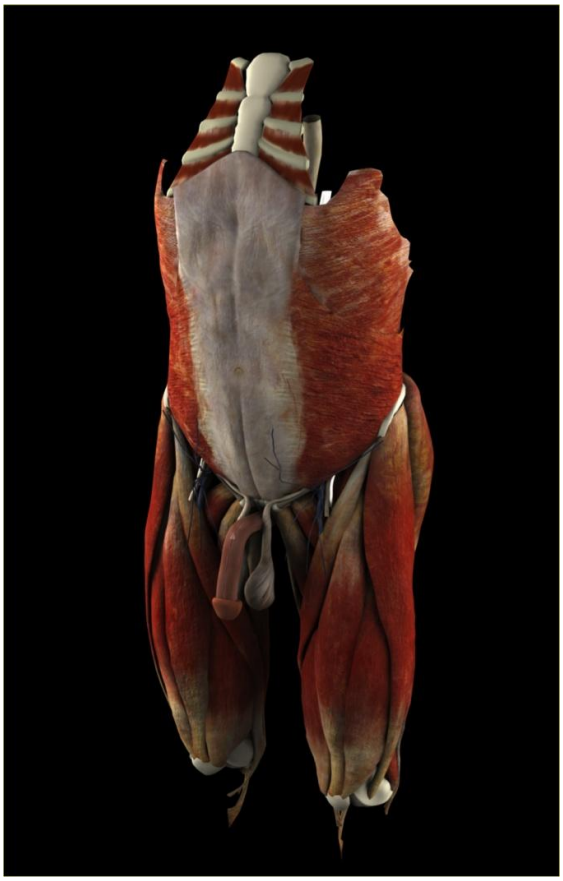

Figure 6. Prototype end-reconstruction derived from scan data and digital photography from inguinal canal, external genitalia and anterior thigh dissections.

References

[1] Beckmann EC. CT scanning the early days, Br J Radiol 2006; 79:5-8.

[2] Hinshaw WS, Bottomley PA, Holland GN.Radiographic thin-section image of the human wrist by nuclear magnetic resonance, Nature 1977; 270:722-3.

[3] Geva TG. Magnetic resonance imaging: historical perspective, Journal of Cardiovascular Magnetic Resonance; 8:573-80.

[4] Park,J S, Chung MS, Hwang SB, Shin BS. The visible Korean human: its techniques and applications, Clinical Anatomy 2006; 19(3):216-24.

[5] Spitzer VM, Whitlock DG. Atlas of the Visible Human Male: Reverse Engineering of the Human Body, 1998. Sadbury, Jones &Barlett

[6] Zhang SX, Heng PA, Liu ZJ, Tan LW, Qui MG, Li QY, Liao RX, Li K, Cui GY, Guo YL, Yang, XP, Liu GJ, Shan JL, Liu JJ, Zhang WG, Chen XH, Chen JH, Wang J, Chen W, Lu M, You J, Pang XL, Xiao H, Xie YM, Cheng JCY. The Chinese Visible Human (CVH) datasetsincorporate technical and imaging advances on earlier digital humans, Journal of Anatomy 2004; 204(3):165-73.

[7] Hieu LC, Sloten JV, Hung LT, Knanh L, Soe S, Zlatov N, Phuoc LT, Trung PD. Medical Reverse Engineering Applications and Methods. 2nd International Conference on Innovations, recent Trends and Challenges in Mechatronics, Mechanical Engineering and New High-Tech Products Developments. Sep 23-24, 2010 Bucharest, Romania

[8] Imelińska C, Downes MS, Yuan W. Semi-automated color segmentation of anatomical tissue, Computerized Medical Imaging and Graphics 2000; 24:173-80.

[9] Pham DL, Xu C, Prince JL. Current methods in medical image segmentation. Annual Review of Biomedical Engineering 2000; 2:315-37.

[10] Imelińska C, Molholt P. Incorporating 3D virtual anatomy into the medical curriculum. Communications of the ACM 2005; 48(2):50-4.

[11] López-Cano M, Rodríguez-Navarro J, Rodríguez-Baeza A, Armengol-Carrasco M, Susín A. A real-time dynamic 3D model of the human inguinal

region for surgical education, Computers in Biology and Medicine 2007; 37:1321-26.

[12] Sakellariou S, Ward BM, Charissis V, Chanock D, Anderson P. Design and Implementation of Augmented Reality, Environment for Complex Anatomy Training: Inguinal Canal Case Study. Virtual and Mixed Reality 2009; 605-614.

[13] Beylot P, Gingins P, Kalra P, Thalmann NM, Maurel W, Thalmann D, Fasel J. 3D interactive topographical modeling using visible human dataset, Eurographics 1996; 15(3): 33-44.

[14] Jastrow H, Vollrath L. Teaching and learning gross anatomy using modern electronic media based on the visible human project, ClinAnat 2003; 16(1):44-54.

[15] Beveridge E, Ma M, Rea P, Bale K, Anderson P. 3D Visualization for Education, Diagnosis and Treatment of Iliotibial Band Syndrome. In the Proceedings of the IEEE International Conference on Computer Medical Applications (ICCMA 2013), Sousse, Tunisia, 20-22 January 2013. ISBN: 978-1-4673-5213-0, DOI: 10.1109/ICCMA.2013.6506143.

[16] Chang, M.C., Trinh, N.H., Fleming, B.C., and Kimia, B. B. Reliable Fusion of Knee Bone Laser Scans to Establish Ground Truth for Cartilage Thickness Measurement. In SPIE Medical Imaging (Image Processing, Proceedings of SPIE Volume 7623). San Diego, CA. Feb. 2010.

[17] Patel KM, Moxham BJ. Attitudes of professional anatomists to curricular change, ClinAnat 2006;19:132–41.

[18] Fitzgerald JE, White MJ, Tang SW, Maxwell-Armstrong CA, James DK. Are we teaching sufficient anatomy at medical school? The opinions of newly qualified doctors, ClinAnat2008; 21:718-24.

[19] Supplementary advice to Tomorrow's Doctors 2009 [accessed 14th October 2013] Available from:http://www.gmc-uk.org/Assessment_in_undergraduate_web.pdf_38514111.pdf

[20] Kluchova D, Bridger J, Parkin IG. Anatomy into the future, BratislLekListy 2000;101(11):626-29.

[21] Turney BW (2007) Anatomy in a modern medical curriculum, Ann R CollSurg Engl. 2007; 89:104-107

[22] Sugand K, Abrahams, P. and Khurana, A.The anatomy of anatomy: A review for its modernization, Anatomical Sciences Education 2010; 3(2):83-93.

[23] VisibleBody [accessed the 14 October 2013] Available from: http://www.visiblebody.com

[24] 3D4Medical [accessed the 14 October 2013] Available from: http://www.3d4medical.com

[25] Cyber Anatomy [accessed the 14 October 2013] Available from: http://cyber-anatomy.com

[26] Primal Pictures [accessed the 14 October 2013] Available from: http://www.primalpictures.com/

[27] Anderson P, Chapman P, Ma M, Rea P. Real-time medical visualization of human head and neck anatomy and its applications for dental training and simulation, Current Medical Imaging Reviews 2013; ISSN 1573-4056 (In Press).

[28] RCUK and Universities UK. Big Ideas for the Future. June 2012. [accessed the 14 October 2013] Availablefrom: http://www.rcuk.ac.uk/Publications/reports/Pages/BigIdeas.aspx

[29] Anatomy Act 1983, [accessed the14 October 2013] Available from:http://www.legislation.gov.uk/ukpga/1984/14/pdfs/ukpga_19840014_en.pdf

[30] Human Tissue (Scotland) Act 2006. [accessed the 14 October 2013] Available from: http://www.legislation.gov.uk/asp/2006/4/pdfs/asp_20060004_en.pdf

[31] PolyWorks. [accessed the 14 October 2013] Available from: http://www.innovmetric.com/polyworks/3D-scanners/home.aspx

[32] PolyWorks. [accessed the 14 October 2013] Available from: http://www.innovmetric.com/polyworks/3D-scanners/home.aspx

[33] Gerth, R.J. (2005) Virtual functional Build For Body Assembly. ASME 2005 Mechanical Engineering Congress and Exposition. Nov 5-11, Orlando, Florida.

[34] Perceptron, 2011.Scanworks [accessed the 14 October 2013] Available from: http://www.perceptron.com/index.php/en/-industrial/3d-scanning-solutions-g/manual-3d-scanning.html Europac3Dimensional, 2011.

[35] Case Studies [accessed the 14 October 2013] Available from: http://www.europac3d.com/casestudies.html

[36] Temkin B, Acosta E, Malvankar A, Vaidyanath S. An interactive three-dimensional virtual body structures system for anatomical training over the internet ClinAnat 2006; 19:267-74.

[37] Venuti J, Imelińska C, Molholt P. New views of male pelvic anatomy: role of computer generated 3D imagesClinAnat 2004; 17:261-71.

[38] Heng PA (2007) Advances in visible human based virtual medicine, Digital Human Modeling 2007; 4561: 623- 32.

ISSN: 2321-8169
2265 – 2276

[39] Kang HS, Kim BH, Ryu FW, Hong SH, Chung HW, Cho SY, Kim YH, Hwang SI, Feong DK, Shin YG. The Visible Man: Three- Dimensional interactive musculo-skeletal anatomical atlas of the lower extremity, RadioGraphics 2000; 20:279-86.

[40] Biasutto SN, Caussa LI, Criado del Río LE.Teaching anatomy: cadavers vs. computers?, Ann Anat 2006; 188:187-90.

[41] Gorman PJ, Meier AH, Krummel TM.Simulation and virtual reality in surgical education: real or unreal?, Arch Surg 1999; 134:1203-08.

[42] Satava RM. Virtual endoscopy diagnosis using 3-D visualization and virtual representation, SurgEndosc1996; 10:173-4.